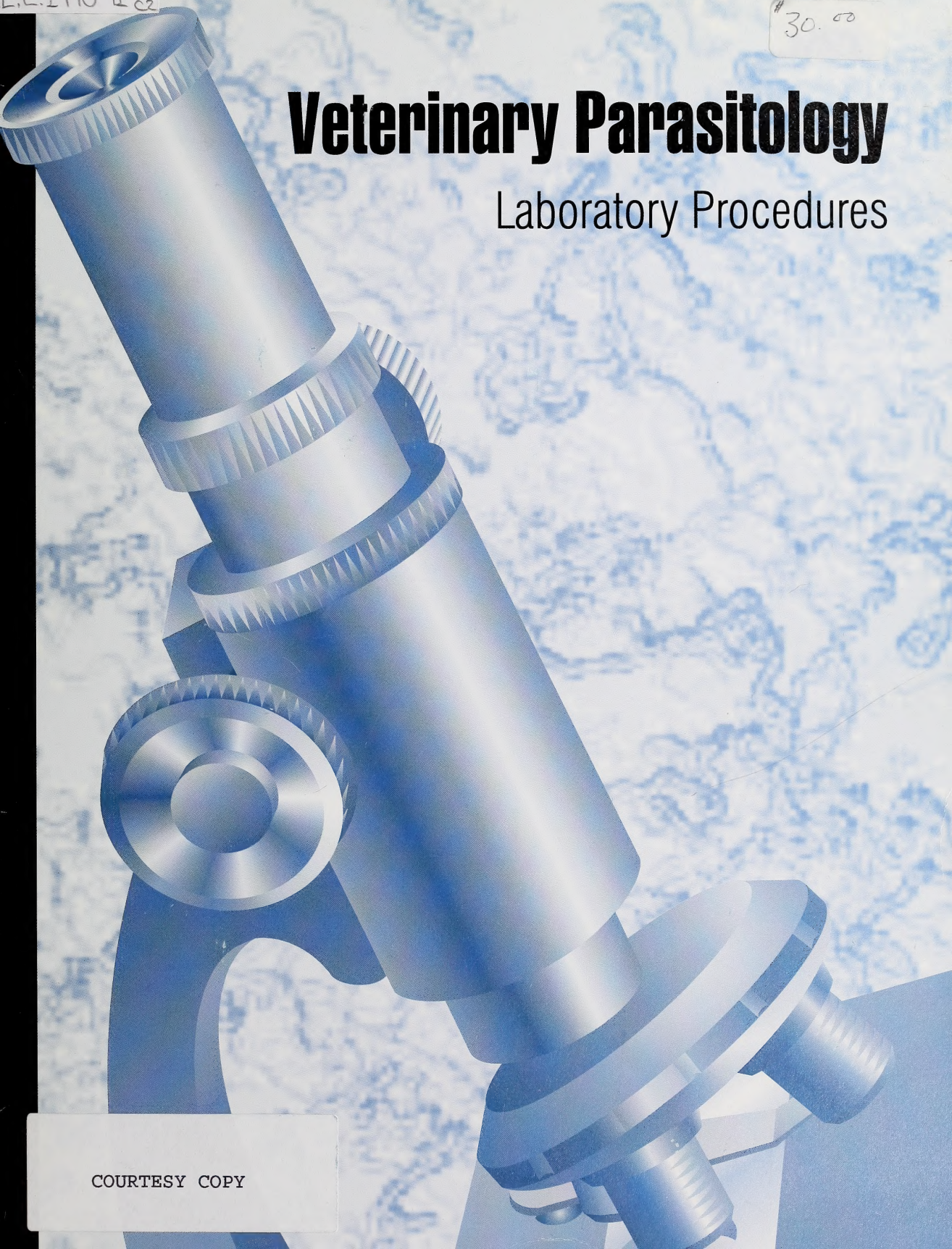


L.2.1998-91 c2

#30.00

Veterinary Parasitology

Laboratory Procedures



COURTESY COPY



Digitized by the Internet Archive
in 2016

<https://archive.org/details/veterinaryparasi00kenn>

CANADIANA

APR 22 1998

Veterinary Parasitology

Laboratory Procedures

Murray J. Kennedy

John D. MacKinnon

Gary W. Higgs

Alberta

AGRICULTURE, FOOD AND
RURAL DEVELOPMENT
Animal Health Laboratories

Published by:

Alberta Agriculture, Food and Rural Development
Publishing Branch
7000 - 113 Street, Edmonton, Alberta
Canada T6H 5T6

Editor: Chris Kaulbars
Graphic Designer: Joyce Hill
Electronic Composition: Sherrill Strauss

Copyright © 1998. Her Majesty the Queen in Right
of Alberta. All rights reserved.

No part of this publication may be reproduced,
stored in a retrieval system, or transmitted in any
form or by any means, electronic, mechanical
photocopying, recording, or otherwise without
written permission from the Publishing Branch,
Alberta Agriculture, Food and Rural Development.


ISBN 0-7732-6136-2

Printed March 1998



H

owever solid a diagnosis may appear, it is worthless if its foundations are not well laid.



[Faint, illegible text, likely bleed-through from the reverse side of the page.]

Table of Contents

Introduction	1
Blood Specimens	3
Introduction	3
Specimen Collection	3
Making Blood Smears	4
Staining Blood Smears	4
Concentration Procedures	6
Fecal Specimens	9
Specimen Collection	9
Protozoa in Feces	10
Temporary Slides	10
Staining Permanent Slides	14
Mucosal Impression Smear	16
<i>Giardia</i>	16
<i>Cryptosporidium</i> sp.	18
Coccidia in Feces	20
Concentration/Flotation Procedures for Intestinal Nematodes and Coccidia	20
Egg Detection	23
Sedimentation Procedures	30
Fecal Egg Counts – Background	33
Species Variations	35
The Skin	43
Introduction	43
Mites	43
Ticks, Lice, Fleas and Keds	45
Beneath the Skin	46
Myiasis	46
Nematodes (<i>Onchocerca</i>)	46
Muscle	49
Introduction	49



Table-Of-Contents

1. Introduction

2. Literature Review

3. Methodology

4. Results

5. Discussion

6. Conclusion


7. References

8. Appendix

9. Glossary

10. Index

Intestine	51
Introduction	51
Protozoa	51
Total Worm Count	53
Mucosal Scraping of Abomasum	53
Swabs	54
Digest Procedures	54
<i>Ollulanus tricuspis</i> in Cats	55
Sedimentation Procedures	56
Mural Transillumination Technique	56
The Eye	58
<i>Thelazia</i> sp.	58
The Mouth	59
Lungs	60
Nasal Passages – Sheep	60
Trachea and Bronchi	60
Lung Parenchyma	61
Body Cavity	63
Liver	64
Urogenital System	65
Herbage Samples	67
Preparing Parasites for Study	69
Parasite Specimens	69
Tapeworms	69
Nematodes and Flukes (Trematodes)	69
Protozoa – <i>Neospora</i>	69
Appendix I	70
Appendix II	72
References	75



11	Introduction
12	Chapter 1
13	Chapter 2
14	Chapter 3
15	Chapter 4
16	Chapter 5
17	Chapter 6
18	Chapter 7
19	Chapter 8
20	Chapter 9
21	Chapter 10
22	Chapter 11
23	Chapter 12
24	Chapter 13
25	Chapter 14
26	Chapter 15
27	Chapter 16
28	Chapter 17
29	Chapter 18
30	Chapter 19
31	Chapter 20
32	Chapter 21
33	Chapter 22
34	Chapter 23
35	Chapter 24
36	Chapter 25
37	Chapter 26
38	Chapter 27
39	Chapter 28
40	Chapter 29
41	Chapter 30
42	Chapter 31
43	Chapter 32
44	Chapter 33
45	Chapter 34
46	Chapter 35
47	Chapter 36
48	Chapter 37
49	Chapter 38
50	Chapter 39
51	Chapter 40
52	Chapter 41
53	Chapter 42
54	Chapter 43
55	Chapter 44
56	Chapter 45
57	Chapter 46
58	Chapter 47
59	Chapter 48
60	Chapter 49
61	Chapter 50
62	Chapter 51
63	Chapter 52
64	Chapter 53
65	Chapter 54
66	Chapter 55
67	Chapter 56
68	Chapter 57
69	Chapter 58
70	Chapter 59
71	Chapter 60
72	Chapter 61
73	Chapter 62
74	Chapter 63
75	Chapter 64
76	Chapter 65
77	Chapter 66
78	Chapter 67
79	Chapter 68
80	Chapter 69
81	Chapter 70
82	Chapter 71
83	Chapter 72
84	Chapter 73
85	Chapter 74
86	Chapter 75
87	Chapter 76
88	Chapter 77
89	Chapter 78
90	Chapter 79
91	Chapter 80
92	Chapter 81
93	Chapter 82
94	Chapter 83
95	Chapter 84
96	Chapter 85
97	Chapter 86
98	Chapter 87
99	Chapter 88
100	Chapter 89
101	Chapter 90
102	Chapter 91
103	Chapter 92
104	Chapter 93
105	Chapter 94
106	Chapter 95
107	Chapter 96
108	Chapter 97
109	Chapter 98
110	Chapter 99
111	Chapter 100

Introduction

The practice of Veterinary Medicine is changing from treating clinically ill animals to herd health management. Animals in a herd not previously examined for parasites are now routinely checked so that total herd health can be evaluated. Similarly, producer groups involved in joint grazing reserves require that all animals be examined for specific diseases (e.g. trichomoniasis) before entering a reserve. In the past, this routine screening for parasites has not been part of the required examination. Furthermore, with the possibility of parasites developing drug resistance, practitioners are, with increasing frequency, doing follow-up examinations to evaluate the efficacy of their treatments. This increased interest in diagnostic parasitology prompted us to provide guidelines to veterinarians and veterinary technologists for doing diagnostic screening.

Parasitic infections are often diagnosed by observing the larval stages or portions of adult helminths living within a host. Helminth eggs, proglottids and nematode larvae can be found in the feces, urine or saliva of animals. Entire worms can be collected during necropsy. In addition, trophozoites and/or cysts may be collected during similar sampling procedures. To obtain a reliable diagnosis, proper sampling and handling procedures should be followed. Inadequate samples and old or poorly preserved material lead to erroneous conclusions.

This manual gives recommendations for collecting samples and describes diagnostic procedures for isolating parasites infecting domestic animals. The manual explains:

- what constitutes a suitable sample,
- the tissues to be examined,
- the portions to be saved when a disorder is encountered,
- methods of preservation, and
- routine and specialized diagnostic procedures.

We reviewed many procedures and their modifications and selected practical and reliable techniques for use in a general veterinary practice. Procedures requiring extensive and

expensive equipment are excluded. Although most diagnostic tests have shortcomings, they provide valuable diagnostic information when properly interpreted.

The first step to identifying parasitic infections is the proper collection and preservation of specimens prior to the examination. A summary table on the specimen to be submitted and the recommended diagnostic procedure is provided in Appendix I. An alphabetical list of solutions used in this book is provided in Appendix II.

Blood Specimens

Introduction

The parasites covered in this section include protozoa (e.g. *Trypanosoma*) and microfilaria of *Dirofilaria*, *Dipetalonema*, *Setaria* and *Onchocerca*. Although microfilaria do not cause disease themselves, they indicate a patent infection.

Microfilaria, such as *Dirofilaria immitis* and *Dipetalonema recurvatum* in dogs, *Setaria* in cattle, and *Onchocerca* in cattle and horses, occur in the blood. Two species may occur concurrently and must be differentiated because of possible differences in pathogenicity.

Specimen Collection

Parasitemias are diagnosed by examining Giemsa-stained smears of peripheral blood. Blood smears should be prepared immediately and air-dried. Pre-fix the dried smear in absolute methanol, 10% formalin or 70% ethanol to preserve the quality of the smear prior to staining.

Shipping blood samples to a diagnostic laboratory

One thin and one thick blood smear should be collected. Air dry the specimens, and package them in a heavy cardboard or plastic slide mailer.

Diagnostic

One thick and one thin blood smear should be made. The thick smear permits examining larger volumes of blood and is valuable when few parasites are present. Blood cells are packed together in thick smears, so critical study of the morphology of the parasite is difficult. Morphological details of parasites are more easily seen in thin blood smears, but they are less accurate than thick smears in diagnostic work.

Giemsa's is the stain of choice. View stained slides under 100 x magnification. Switch to high dry (450 x) or oil immersion (1000 x) to examine parasites in detail. Screen at least 100 oil immersion fields in both preparations. Light infections may be missed if fewer fields are examined.

Making Blood Smears

Thin Film

1. Place a drop of fresh blood about 25 mm from the frosted end of a 25 x 75 mm slide (Figure 1a).
2. Touch the end of a second slide to the leading edge of the drop (Figure 1b). Capillary action will spread the blood across the width of the slide.
3. Push the second slide horizontally across the first slide at an angle of 20° to 45° (Figure 1c). The film should form a monolayer of cells.
4. Air dry the slide.
5. Stain the slide within 1 hour, or fix the dried smear in absolute methanol for 3 minutes and stain later.

Thick Film

1. Place 2 or 3 drops of blood in the center of a 25 x 75 mm slide.
2. Spread the blood into an even layer with a toothpick.
3. Allow the film to dry. This may take 1 hour or longer.
4. Place the dried smear in distilled water for a few minutes. This will haemolyze the red blood cells and make the parasites more easily seen.

Coverslip Method

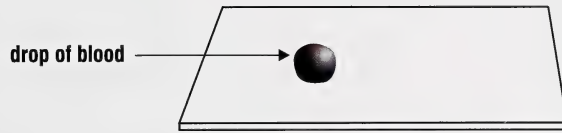
Place a small drop of blood on one coverslip, and place a second coverslip on top of it. Draw the two coverslips apart after the blood has spread. This method gives good blood cell distribution.

Staining Blood Smears

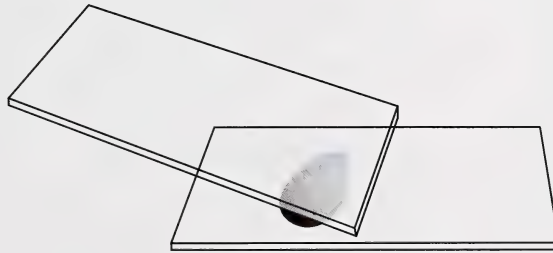
Giemsa Stain

Giemsa (1902) specified Bernthsen's methylene azure, methylene blue and eosin as constituents of his widely-used stain for blood and blood Protozoa. The azure stains lymphocyte cytoplasm light blue. This colour is better represented in Giemsa-stained than in Wright-stained

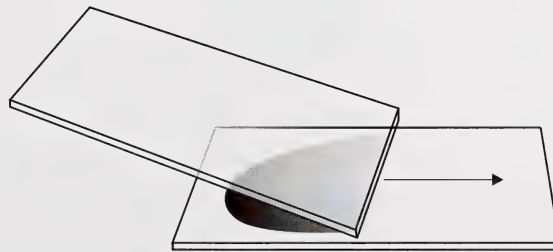
Figure 1
Preparing Blood Smears



a



b



c

*** Note**

Commercial stains require specific staining time. Used stains need longer staining time than freshly-made stains. The correct staining time is determined by trial.

Diff-Quick (Harleco, New Jersey, U.S.A.) is a good alternative for use in the veterinary practitioner's laboratory. Staining takes about 30 seconds to complete (Hart *et al.*, 1992).

**** Note**

A density gradient method for separating microfilariae can be used, but this procedure is difficult. See Muscoplast *et al.*, (1977) for a discussion of this procedure. Dickerson *et al.*, (1990) described a nucleopore filter technique for detecting microfilaria in preserved blood.

preparations (Baker, 1970). However, a good Wright stain is an acceptable substitute. Thick blood smears should be haemolyzed in distilled water before staining.

Procedure

1. Place a dried blood smear in absolute methanol for approximately 10 minutes (Figure 2a).
2. Remove and air dry.
- * 3. Stain the dried slide in Giemsa's stain for 20 to 60 minutes (Figure 2b).
4. Rinse the stained slide in distilled water to remove excess stain (Figure 2c).
5. Allow the stained smear to dry.
6. If you want to use a coverglass, put 1 drop of xylol on the smear, add a drop of Permount and apply the coverglass.

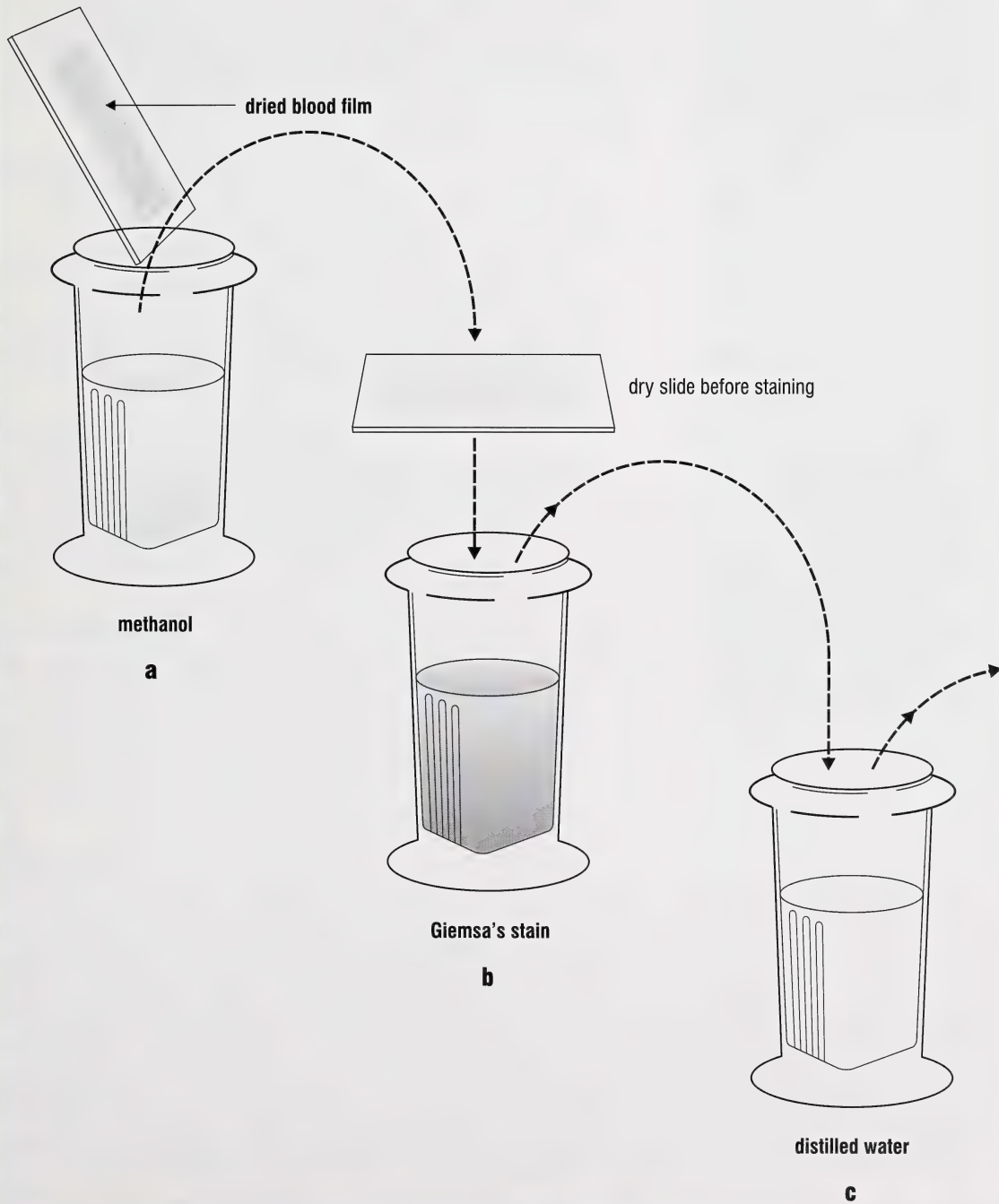
Concentration Procedures

Blood smears and sedimentation techniques are generally used to recover microfilariae. The Whole Blood Concentration or the Knott's procedure are usually employed. In the first method, methylene blue is used to stain microfilariae. In the second, red blood cells are haemolyzed, and unstained microfilariae are concentrated.

Whole-Blood-Concentration Method

1. Place 1 ml of fresh blood into a 15 ml graduated centrifuge tube.
2. Add 3 ml of 3% acetic acid and mix well.
3. Centrifuge at 1500 rpm for 5 minutes.
4. Decant the supernatant.
5. Resuspend the sediment, and record the volume.
6. Place a measured amount of suspended sediment on a slide, add a coverglass and examine under low magnification (40 x).
7. Count all the microfilariae under the coverglass.
8. Determine the number of worms/ml by multiplying your count by the portion of resuspended sediment examined.

Figure 2
Staining Blood Smears



*** Note**

Dipetalonema reconditum has a diurnal periodicity, peaking between 1400 and 1600 hours, and possibly a nocturnal one, peaking between 2000 and 2400 hours (Pennington and Phelps, 1969). *Dirofilaria immitis* is more variable in periodicity (Church *et al.*, 1976).

**** Note**

Fresh blood or blood containing an anticoagulant may be used. Examine preparations at 100 x magnification. Occult dirofilariasis (dirofilariasis with no circulating microfilariae) will give a false negative diagnosis for heartworm infection.

Knott's Technique

This technique is used to concentrate microfilariae,

- * particularly when few microfilariae are present. The Knott's technique produces a clear preparation, making it easy to
- ** count microfilariae.

1. Place 1 ml of fresh blood into a 15 ml centrifuge tube. Add 10 ml of 2% formalin.
2. Shake the mixture well and centrifuge it for 5 minutes at 1500 rpm.
3. Decant the supernatant.
4. Mix the sediment with an equal volume of 1:1000 aqueous methylene blue.
5. Place a small amount of the mixture on a slide, add a coverglass and examine the preparation under the compound microscope.

Fecal Specimens

Fecal samples are examined in stages. First, look for whole parasites or fragments (e.g. tapeworm proglottids) on the surface of the feces. Then examine the feces microscopically for parasite eggs, larvae, oocysts, etc.

Specimen Collection

Normally passed fecals are preferred in clinical parasitology. Fecal samples collected off the ground are unsuitable for diagnostic work. Parasitic nematode larvae migrate from feces onto the ground while free-living nematodes enter the sample and complicate the diagnosis. If the source or age of the fecal sample is unknown, request a fresh sample.

Rectal Samples

Collect fecal samples from the rectum and place each sample into a separate container. Label the sample completely and examine it immediately, or refrigerate it and examine it within 24 to 48 hours.

Preserving Samples


Specimens that cannot be examined immediately or cannot be refrigerated should be preserved in 10% formalin. Formalin preserves trophozoites, cysts, helminth eggs and larvae, which can be detected using concentration techniques or wet-mounts.

Quantity Needed

Fecal consistency and the number of tests required determine the quantity of feces needed. In most cases, two tablespoons of well-formed feces are sufficient for each test requested. Double this amount if the sample is mushy or soft, and triple it if the stool is liquid. Tests should not be done on insufficient material.

Multiple Samples

Helminth eggs, oocysts, and protozoan cysts do not generally pass in the feces continuously. Therefore, several samples should be examined. Additional samples may be necessary



when negative results are obtained on the first sample, but parasitism is still suspected. Parasites with long prepatant periods cause damage before evidence of parasitism is detected in the feces. Three separate specimens are recommended to detect some protozoa (e.g. *Giardia*, *Entamoeba*). To rule out intestinal helminthiasis, examine at least two, and preferably three, specimens. A single negative report does not rule out parasitism.

Protozoa in Feces

Fresh samples are needed to diagnose protozoa. Examine unpreserved fecal samples within one or two hours of passage, especially if the sample is watery. Diarrheic or semiformed feces contain mostly motile trophozoites that disintegrate rapidly. Make two smears from each sample. If *Giardia* sp. is suspected, examine three fresh samples, one collected every second or third day.

Slowing Down Protozoa

The rapid movement of many protozoa is slowed by placing them in a viscous fluid.

Procedure

1. Place 1 drop of fecal suspension on a slide.
2. Add 1 drop of (10%) methyl cellulose solution.
3. Mix well.
4. Apply a coverglass and examine under the microscope.

Temporary Slides

Temporary preparations are used for fecal material or mucosal scrapings for protozoa. Preparations can be viewed without stain, or an iodine stain may be used. Iodine highlights morphological detail necessary to identify protozoa. Wet mounts last for several days when the coverglass is sealed with vaseline.

Procedure

1. Place 1 drop of saline or Lugol's iodine solution in the centre of a 25 x 75 mm glass slide (Figure 3a).
2. Mix a small amount of feces with the saline (Figure 3b). The slurry should be thin enough to read type print through it. *
3. Apply a coverglass to the slurry, keeping the coarse material at the edge of the slide (Figure 3c). Examine the slide using 100 x magnification. **

Nematode, cestode and trematode eggs, or the oocysts of coccidia, may be found using this method. Because the technique does not concentrate oocysts and eggs, it has a low sensitivity for detecting most gastrointestinal parasites.

Sealing Slides

1. Draw a 20 mm square on a piece of paper (Figure 4a).
2. Place a glass slide on the paper, so the square is centered (Figure 4b). With a toothpick, trace the outline of the square with vaseline (Figure 4c).
3. Place a drop of fecal slurry in the centre of a coverglass (Figure 4d).
4. Invert the slide so that the vaseline square is underneath, and lower this onto the coverglass (Figure 4e).
5. Press the slide down gently to seal the coverglass (Figure 4f).

Staining Temporary Slides

Lugol's or Noland's solution can be used to stain protozoa to enhance their morphological detail. The iodine in Lugol's solution stains glycogen granules and nuclei. The gentian violet (= crystal violet) in Noland's solution stains flagella, cilia and nuclei.

Procedure

Mix 1 drop of fecal slurry with 1 drop of Lugol's or Noland's solution. Add a coverglass and examine.

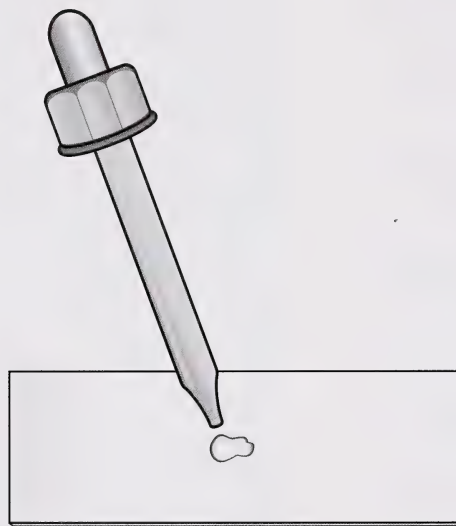
*** Note**

To remove coarse material, hold a 22 x 22 mm coverglass by the edges, tilt the slide slightly and use the coverglass to pull the lumps to one edge

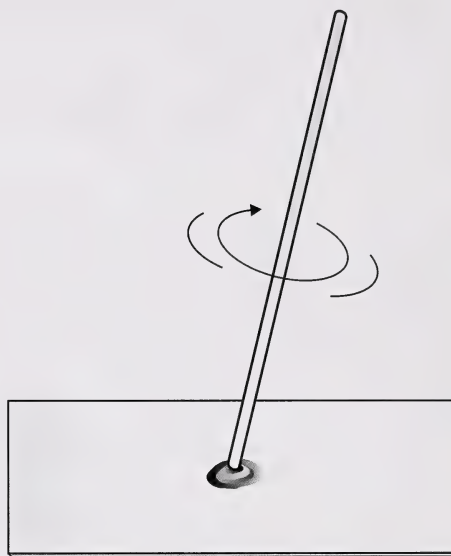
**** Note**

Slides should be scanned systematically from left to right or top to bottom (Figure 3d).

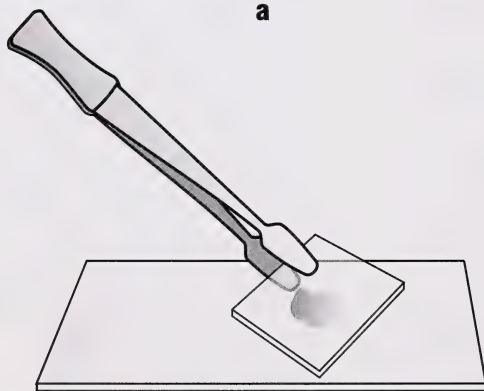
Figure 3
Preparing and Scanning Wet Mounts



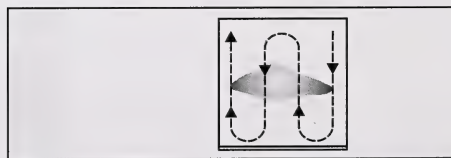
a



b

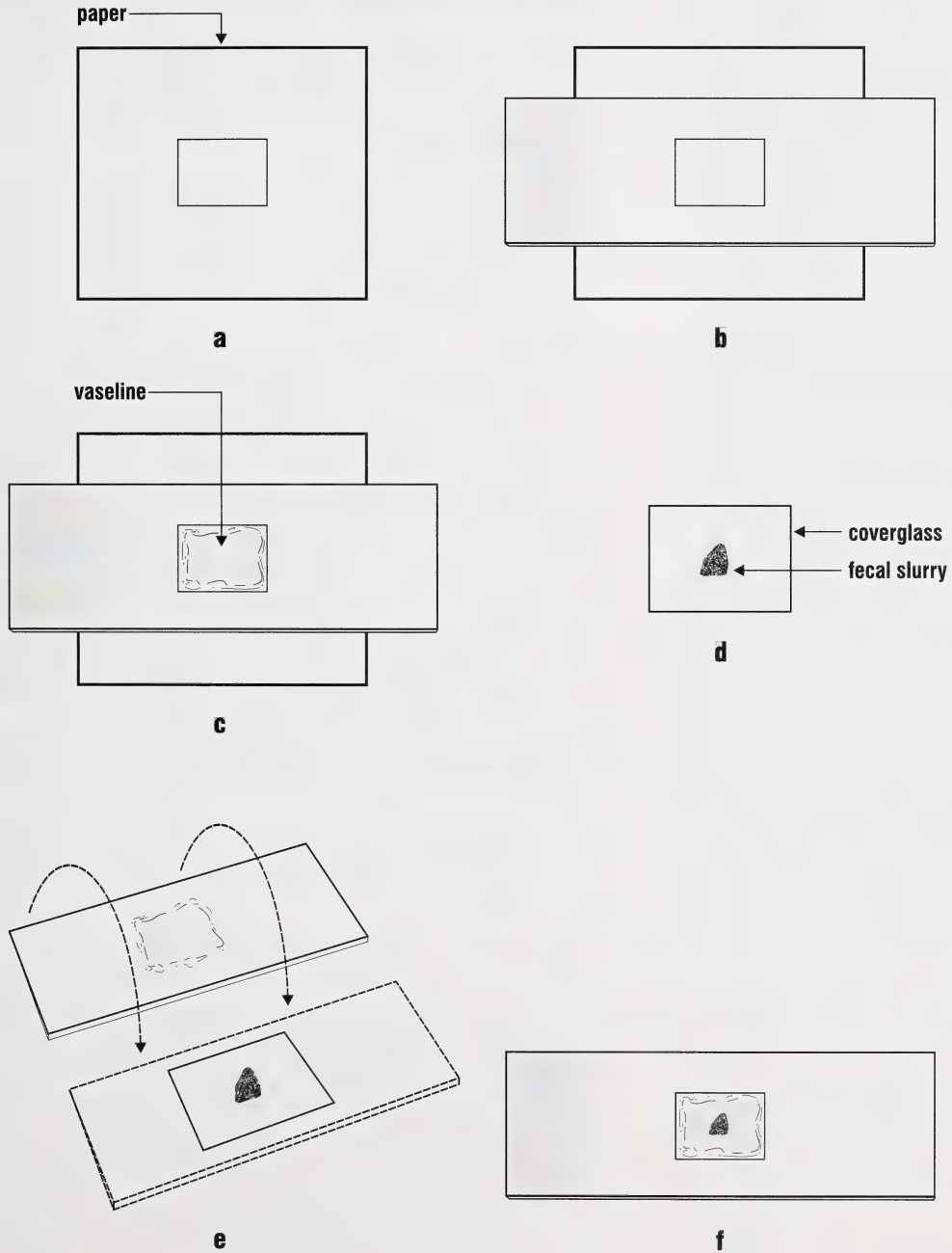



c



d

Figure 4
Sealing Temporary Mounts



- 
- * **Note**
Monitor this step with a microscope until proper destaining is achieved.

Staining Permanent Slides

Fixed and stained smears are required for parasite identification and to document specific cases.

Hematoxylin Stain

Spencer and Monroe's (1961) technique can be used for fecal specimens. Spread a thin layer of Mayer's albumen on a slide before adding the protozoa. The albumen sticks the protozoa to the slide.

Procedure

1. Make a thin fecal smear.
2. Place the slide in Schaudinn's fixative before the smear dries. Let stand for at least 1 hour.
3. Wash in 2 changes of 70% ethanol.
4. Transfer to 0.2% ferric ammonium sulphate for 2 to 4 hours.
5. Wash in 50% ethanol for 3 to 5 minutes, then gently in tapwater for 10 minutes.
6. Transfer the slide to 2% ferric ammonium sulphate for 2 to 4 hours.
7. Wash in 2 changes of distilled water for 3 to 6 minutes each.
8. Stain in hematoxylin for 5 to 10 minutes at 50°C.
9. Wash in 2 changes of tapwater for a total of 3 to 6 minutes.
- * 10. Destain in 2% ferric ammonium sulphate.
11. Wash in tapwater for 10 to 30 minutes.
12. Dehydrate through 50%, 70%, 95%, then 2 changes of absolute ethanol for 3 to 5 minutes each.
13. Clear in xylene.
14. Mount in Permount.

Kohn's Chlorazol Black Method (KCB)

(After Gleason and Healy, 1966; Bullock, 1980)

This one-step fixative-stain method aids in the identification of Protozoa in fecal specimens. The KCB Technique is a good substitute for more time-consuming procedures (Gleason and Healy, 1965).

Procedure

1. Make a fecal smear.
2. Fix and stain in KCB solution for 2 to 4 hours.
3. Drain the slide briefly.
4. Dehydrate in 95% ethanol for 10 to 15 minutes, then in absolute ethanol for 5 minutes.
5. Clear in 2 changes of xylene for 5 minutes each.
6. Mount in Permount.

Trichrome Staining

This is excellent for *Giardia*.

Procedure (After Baker *et al.*, 1987)

1. Collect approximately 5 g of feces.
2. Preserve the feces in polyvinyl alcohol (PVA).
3. Shake the vial vigorously to assure good fecal fixation. Fix for at least 15 minutes before staining.
4. Centrifuge the fixed material for 5 minutes at 800g.
5. Streak the fecal sediment on a microscope slide and air dry.
6. Place the air-dried slide in 70% ethanol plus iodine for 5 to 10 minutes.
7. Transfer the slide to 70% ethanol for 5 minutes.
8. Place the slide in a second 70% ethanol for 3 minutes.
9. Stain the slide in trichrome for 10 minutes.
10. Dip the stained slide in 90% ethanol plus acetic acid for 1 to 3 seconds, and then drain briefly.
11. Immediately dip several times in absolute ethanol.
12. Place in 2 changes of absolute ethanol for 3 minutes each.

* Note

Bacteria and background debris stain black; protozoa blue-black to green.

** Note

The fecal:PVA ratio should be 1:3.

*** Note

The 70% ethanol containing iodine removes the mercuric chloride. If mercuric chloride is not removed, it will precipitate on the slide as crystalline material.

* **Note**

If a large amount of fat is present, use an ethyl acetate sedimentation technique.

13. Place in xylene for 5 to 10 minutes.
14. Place in second xylene for 5 to 10 minutes.
15. Add Permount and a coverglass.

Mucosal Impression Smear

Coccidiosis is diagnosed by flotation techniques or by examining stained histological sections. Mucosal impression smears are a useful adjunct to diagnosing prepatent infections.

Make mucosal smears from several locations within the intestine, especially areas showing lesions. Smears from animals that have been dead for some time are difficult to interpret.

Procedure

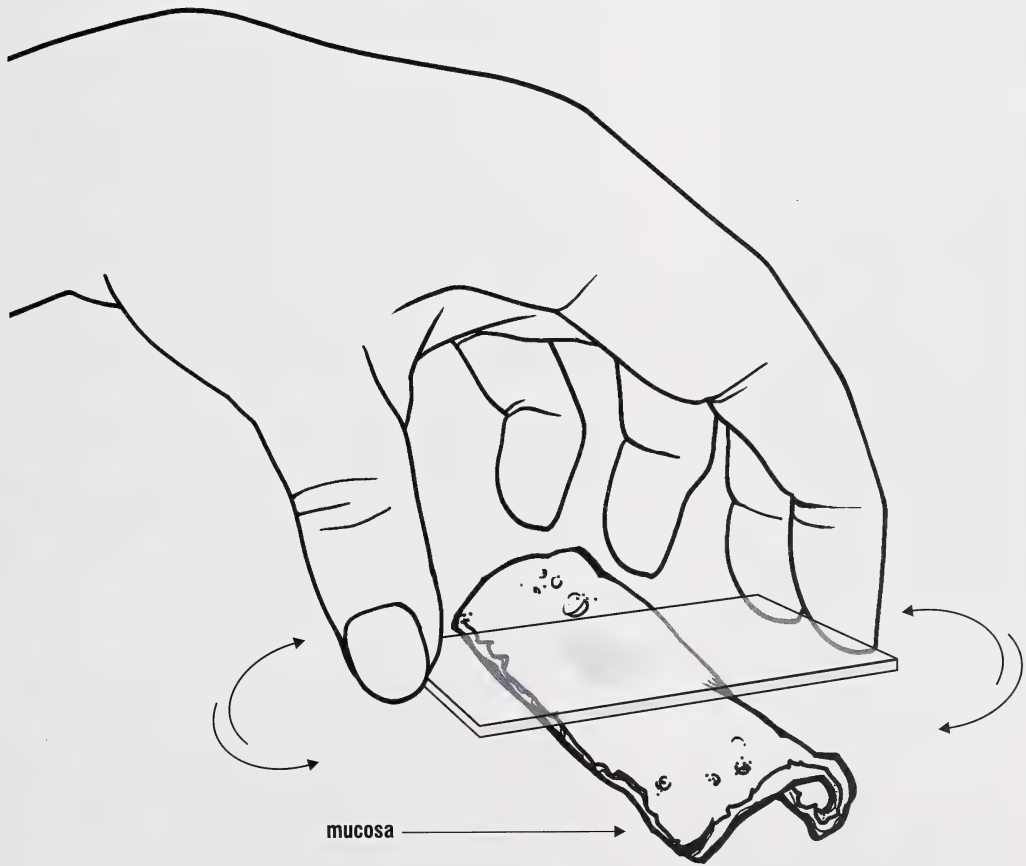
1. Blot the mucosal surface gently with a paper towel to remove excess fluid and debris.
2. Press a microscope slide firmly against the mucosa and rotate the slide slightly (Figure 5).
3. Lift the slide directly away from the mucosa.
4. Air dry the smear.
5. Stain with Kinyoun stain.

Giardia

Three techniques are used to detect *Giardia*: wet smear, Wheatley's trichrome-stained smear, and a modified zinc sulphate concentration technique. Trophozoites are fragile and should be sought in fresh feces or intestinal material. Trophozoites may become inactive within three hours following collection, and diagnosis may be impossible after sixteen hours. Stool samples should be collected and examined on at least three different days to confirm giardiasis.

The direct smear is used for samples collected within one hour of defecation. The sensitivity is low, about 20%, but the

Figure 5
Making Impression Smears



* **Note**

Cysts of *Giardia* collapse and trophozoites are destroyed in saturated sugar solution.

** **Note**

Trophozoites and cysts are excreted intermittently in the feces.

*** **Note**

Respiratory invasion by *Cryptosporidium* has been described (Mascaro, *et al.*, 1994). Fresh lung tissue can be examined under light microscopy for cryptosporidia. In cattle, look for them in the microvillus border of unciliated epithelial cells from terminal and respiratory bronchioles.

assay is quick and can be done while the animal is present. Repeating the assay on fresh fecal samples on three different days increases the sensitivity to approximately 43% (Zimmer and Burrington, 1986).

Use the trichrome procedure when you cannot examine the smear immediately or if the infection must be documented.

Giardia can be preserved in air-dried smears and stained later if necessary. Mucosal smears of the small intestine are excellent. Routine haematological stains are good for both trophozoites and cysts. Commercial stains such as Diff-Quick [Harleco, Gibbstown, N.J., U.S.A.] are useful.

- * The modified zinc sulphate concentration technique detects about 70% of infections on one sampling. Repeating the procedure on feces collected on three different days increases the sensitivity to approximately 94% (Zimmer and
- ** Burrington, 1986).

***Cryptosporidium* sp.**

Ma and Soave (1983) recommend a three-step stool examination method to diagnose intestinal cryptosporidiosis:

- ***
- an iodine-stained wet mount followed by
- Kinyoun acid-fast staining and
- coverglass flotation of oocysts in Sheather's sucrose

All three steps may be required for a diagnosis (Table 1). A negative result may occur in Steps 1 and 2 when only a few oocysts are present. Oocysts may be passed intermittently, so a negative fecal examination should be repeated within three or four days if cryptosporidiosis is still suspected.

The formalin-ethyl acetate technique is excellent for concentrating cryptosporidial oocysts in feces (Mtambo *et al.*, 1992). Stain the sediment with modified Ziehl-Neelsen technique to increase its sensitivity.

Sheather's sugar flotation concentrates oocysts in feces (McNabb, 1985). The unstained oocysts can be seen just beneath the coverslip.

Diagnosis of *Cryptosporidium* can be done on Giemsa-stained impression smears of the ileal mucosa or tissue sections of the ileum stained with hematoxylin and eosin. The smears may be stained by a Giemsa technique or by standard acid-fast techniques. The acid-fast procedure outlined below takes about five minutes to perform.

Giemsa's Procedure

1. Make an impression or fecal smear or scraping of the ileal mucosa.
2. Air dry.
3. Fix in 10% buffered formalin.
4. Follow Giemsa's staining procedure for preparing slides.

Yeast cells, which resemble oocysts, stain light-blue to purple.

Modified Kinyoun Acid-Fast Stain for Cryptosporidia

Procedure

1. Fix the smear with gentle heat.
2. Stain for 1 minute with Carbol fuchsin.
3. Wash with tapwater.
4. Decolorize with 10% H₂SO₄. This happens rapidly!
5. Wash with tapwater.
6. Counter-stain with Light Green SF Yellowish stain (0.3%) for 20 to 30 seconds.
7. Wash gently with tapwater, dry, add a drop of Permout and a coverglass.
8. Examine under high dry (40 x objective) magnification.

Oocysts can be stored in 2.5% potassium dichromate [1 part feces to 2 parts potassium dichromate (Wilson and Acres, 1982)]. Examine the sample by mixing the fecal-dichromate solution with Sheather's saturated sugar and centrifuge the mixture. The effect of potassium dichromate on the

Table 1

Characteristics of *Cryptosporidium* using different methods of detecting oocysts

Procedure	Oocysts	Yeast
Iodine Wet Mount	colourless	brown
Kinyoun Acid-fast	red	green
Sheather's	refractile bodies 5µm diam., distinct halo	—
Giemsa		light blue to purple

Comment

Prepare at least one slide each from the mucosa and feces. Cryptosporidia may be present in the fecal smear and not in the impression smear when the intestine is autolytic.

* Note

Stain kits are available commercially:
e.g. The AFB (acid-fast) stain kit – Volu-sol Medical Industries, Henderson, Nevada, U.S.A.

Diff-Quik – Harleco, Gibbstown, New Jersey, U.S.A.

Comment

Frozen fecal specimens cannot be used for staining.

*** Note**

Continuous aeration or agitation of the culture will improve results.

Comment

Two criteria are used to assess the usefulness of a fecal analysis procedure:

- first, efficiency, the proportion of eggs recovered from a sample;
- second, sensitivity, the proportion of truly infected animals (samples) in the screened population that are identified.

Comment

The efficiency of a flotation procedure is influenced by sample size, fecal texture, degree of fecal contamination, flotation solutions and time of flotation.

stainability of oocysts with iodine or modified Kinyoun acid-fast stain is unknown. Use fresh fecal material for these procedures.

Coccidia in Feces

Sporulating Oocysts

1. Mix approximately 1 g of feces with 2.5% potassium dichromate solution.
2. Place the mixture in a petri dish.
3. Let stand at room temperature for approximately 5 days. The length of time will depend on the species present and the temperature.
4. Transfer the culture to a 15 ml centrifuge tube and centrifuge at 1500 rpm for 3 to 5 minutes.
5. Decant the supernatant.
6. Add Sheather's sugar solution to the sediment and mix well.
7. Centrifuge at 1500 rpm for 3 minutes.
8. Apply a glass rod to the surface film.
9. Transfer the drop from the rod to a microscope slide.
10. Apply a coverglass and examine under low magnification.

Concentration/Flotation Procedures for Intestinal Nematodes and Coccidia

Fecal specimens may be processed fresh or preserved in 10% formalin for later processing.

Different parasites and eggs concentrate differently. The concentration methods used fall into two general categories: flotation and sedimentation. Nematode eggs and oocysts concentrate better using flotation procedures. Sedimentation procedures work best for trematode eggs. Thin-shelled trematode eggs collapse in the hypertonic solutions used in flotation-concentration techniques (Leipee, 1949).

Flotation techniques improve parasite detection by concentrating the eggs or oocysts passed in feces. The Wisconsin and modified Cornell techniques have good efficiency and sensitivity (Egwan and Slocombe, 1981, 1982). The accuracy of fecal egg or oocyst counts can be improved by increasing the number of replicates.

Three techniques (McMaster's, Wisconsin and Direct Centrifugal Flotation – DCF) are frequently used to count nematode eggs in feces. Levine *et al.*, (1960) found the counts obtained by the McMaster's technique were accurate indices of the number of eggs actually present; the counts obtained by the DCF technique are lower. The advantage of the DCF technique is that it detects infections containing only a few ova (Levine *et al.*, 1960).

Various sugar or salt solutions are used to concentrate parasite eggs and oocysts. Solutions of specific gravity (s.gr.) 1.22-1.35 are used for routine laboratory work, with a s.gr. of 1.27 being a good choice (O'Grady and Slocombe, 1980). If the s.gr. is too high, excess debris is floated.

Sheather's Procedure

1. Mix 5 g of fresh feces with 15 ml of water (Figure 6a). *
2. Strain the suspension through a tea strainer or two layers of gauze (Figure 6b).
3. Half fill a 15 ml centrifuge tube with the strained suspension.
4. Add Sheather's sugar solution to a level slightly below the top of the tube and mix thoroughly.
5. Add sufficient sugar solution to form a meniscus that bulges just above the top of the tube (Figure 6c).
6. Place a coverglass on the meniscus so that no air bubbles are formed (Figure 6d).
7. Centrifuge at 1500 rpm for 3 minutes.
8. Remove the coverglass by a direct upward motion (Figure 6e).
9. Make a slide and examine under medium magnification (100 x). **

Comment

We recommend a sugar solution because it gives good flotation and does not crystallize quickly.

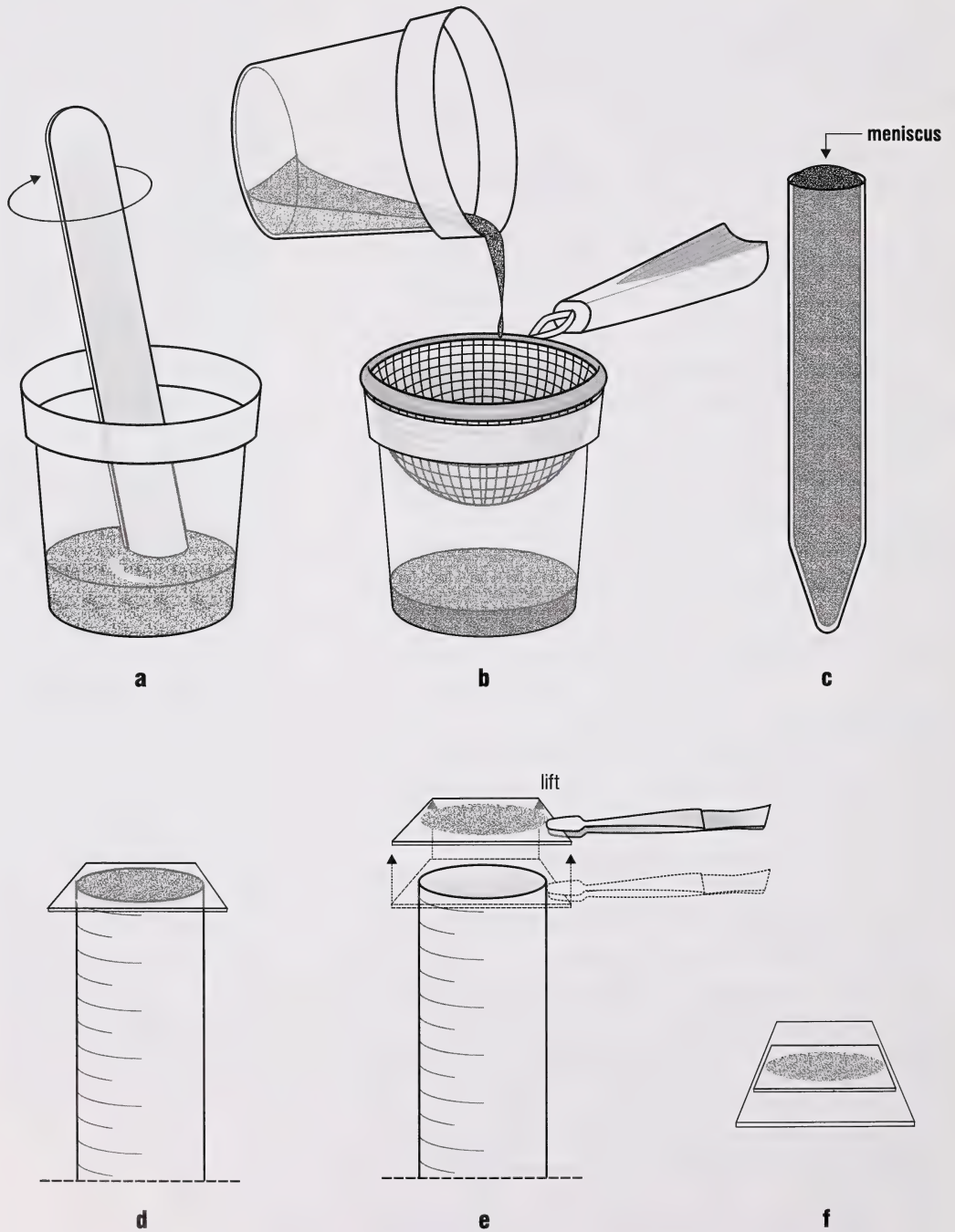
* Note

Sheep and goat pellets should be softened in water for 10 to 15 minutes before mixing.

** Note

A drop of Lugol's Solution may be added.

Figure 6
Sheather's Flotation Technique



Egg Detection

Modified Willis Technique

(After Uhlinger, 1993)

1. Place 1g of feces in a narrow cylinder.
2. Mix with a saturated sugar solution, s.gr. > 1.2.
3. Place a coverglass on the surface of the liquid.
4. Let stand for 20 to 40 minutes.
5. Remove the coverglass, place it on a slide and examine it under medium power of your microscope.

This flotation procedure is easy to perform. Results are evaluated subjectively as 0 to +4 or on a none-slight-moderate-heavy evaluation scale. If the procedure is repeated several times on the same feces, a variation from +1 to +4 may occur (see Uhlinger, 1993). The commercially available Fecalizer® (Evsco Pharmaceuticals, N.J., U.S.A.) is a modification of this procedure that makes collecting feces easy for the pet/animal owner.

Quantitative Fecal Procedures

Quantitative procedures are preferable to subjective procedures. In quantitative procedures, a weighed amount of feces is suspended in a set volume of saturated solution.

Cornell-Wisconsin Centrifugation Technique

(After Egwang and Slocombe, 1982)

1. Mix 5 g of feces with 12 ml water.
2. Strain mixture through a tea strainer.
3. Rinse container with 2 to 5 ml of water and pour through the strainer.
4. Press the wet fecal material with a tongue depressor to squeeze out as much water as possible.
5. Pour the strained material into a 15 ml centrifuge tube.
6. Centrifuge feces in water for 3 minutes at 264g.
7. Discard the supernatant.

* **Note**

The number of eggs found is divided by 5 to determine the number of eggs per gram of feces. The number may be multiplied by 1.6 since the technique has a recovery rate of 62.5%.

Comment

The number of ova in the chamber is corrected for the weight of the sample and the dilution factor. A modification of this technique involves mixing 1 g of feces in 30 ml of saturated solution. Uhlinger (1993) noted that depending on the technique used, and the number of readings per sample, the minimum level of detection for the McMaster's test is 50 to 200 eggs per gram, and the results from repeated samples may vary as much as 50%. There is a poor correlation between the results of Willis and McMasters.

** **Note**

A modification of this technique uses 1 g of feces in 30 ml of saturated solution.

8. Fill the centrifuge tube 1/2 full with saturated sugar solution (s.gr. 1.27). Use an applicator stick to thoroughly mix the sediment with sugar solution.
9. Fill the tube 3/4 full with more saturated sugar solution and mix thoroughly.
10. Place the tube in the centrifuge and add sugar drop-by-drop until a meniscus is formed.
11. Place a 22 mm square coverglass over the meniscus.
12. Centrifuge for 5 minutes at 264g.
13. After centrifuging, lift the coverglass straight up and put it on a glass slide.
14. Examine the slide at 100 x magnification and count the eggs.

Modified Wisconsin Method

(After Cox and Todd, 1962)

- ** 1. Weigh out a 5 g (cattle) or 2 g (sheep) fecal sample.
2. Pour 22 ml of water into a beaker and add the feces.
3. Mix until the feces is completely broken apart.
4. Pour the mixture through a tea strainer into a second beaker.
5. Press the material remaining in the strainer with a spatula.
6. Rinse the first beaker with 8 ml of water and pour this mixture through the material in the strainer.
7. Press the material in the strainer until it is dry.
8. Stir the strained material and immediately pour all the contents of the beaker equally into two 15 ml centrifuge tubes. If the tubes are not full, wash the beaker with water and finish filling the tubes.
9. Centrifuge the tubes at 1500 rpm for 10 minutes.
10. Decant both tubes. Do not pour off the fine material at the top of the sediment.
11. Fill one half of each tube with sugar solution (s.gr. 1.27). Mix thoroughly.
12. Fill the tubes with sugar solution and place them into the centrifuge.

13. Add sugar solution to the tubes to form a meniscus. Add a 22 mm square coverglass on top. *
14. Centrifuge at 1500 rpm for 10 minutes.
15. Remove both coverglasses by lifting straight up and place them on a glass slide.
16. Count the nematode eggs and oocysts under each coverglass. The counts for each coverglass should be kept separate.

McMaster's Technique

(After Levine et al, 1960)

1. Place a few grams of feces in a shell vial and add 28 ml of water.
2. Mix thoroughly.
3. Place 1 ml of the suspension in a graduated cylinder and add 1 ml of Sheather's sugar solution.
4. Mix thoroughly.
5. Fill a McMaster's counting chamber with suspension (Figure 7a). The marked area of the chamber should be completely filled (Figure 7b).
6. Let the chamber stand for a few minutes to allow the eggs and oocysts to float to the top.
7. Place the chamber under the microscope and count all the eggs in the marked area.
8. Repeat the counts until the average is within 10% of the average obtained in the previous count. It may be necessary to count 3 to 5 chambers.
9. Multiply the average by 200 if your chamber is 1.5 mm high (ie., 150 mm³) or 300 if it is 1.0 mm high (100 mm³).

Modified McMaster's Technique

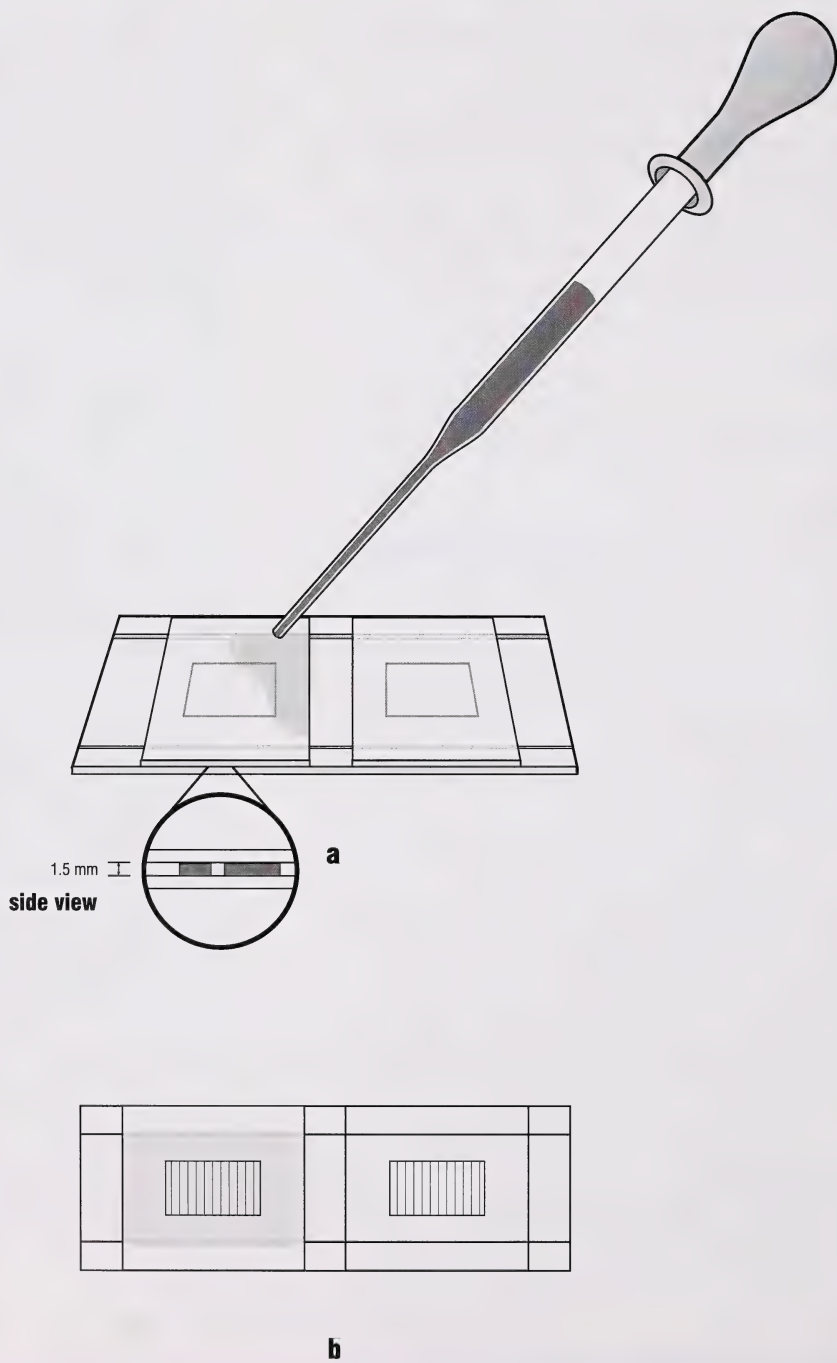
The modified McMaster's technique as described in MAFF (1986) has a sensitivity of 10 epg.

1. Weigh out 4.5 g of feces.
2. Add 40.5 ml of water and mix thoroughly.

* Note

There should be enough fluid so that no air bubbles form under the coverglass, and fluid does not overflow and run down the side of the tube.

Figure 7
McMaster's Technique



3. Pour the mixture through a 100 mesh sieve (household coffee/tea strainer) and catch the strained fluid in a bowl (discard debris left on the sieve).
4. Stir the strained fluid and pour 15 ml into a centrifuge tube. Centrifuge for 2 minutes at 1500 rpm and discard the supernatant.
5. Mix the sediment to form a homogenous sludge at the bottom of the tube, then fill the tube with saturated salt solution.
6. Mix the contents of the tube thoroughly by inverting it 5 or 6 times (do not shake) with your thumb over the end. Immediately withdraw sufficient fluid with a pipette and run it into one chamber of a McMaster counting slide. Mix, and withdraw a second sample for the other chamber.
7. Count the eggs in the marked area of both chambers.

Zinc Sulphate Technique for *Giardia*

This procedure uses a lower specific gravity (s.gr. 1.18) than for concentrating oocysts or nematode eggs (s.gr. 1.2 to 1.25). *Giardia* is shed intermittently in the feces. Stool samples should be collected on three different days and examined. If the first examination is negative, repeat the assay twice on fecals collected a few days apart (Zimmer and Burrington, 1986; Baker *et al.*, 1987). Trophozoites are more numerous in diarrheic stools and cysts in formed stools.

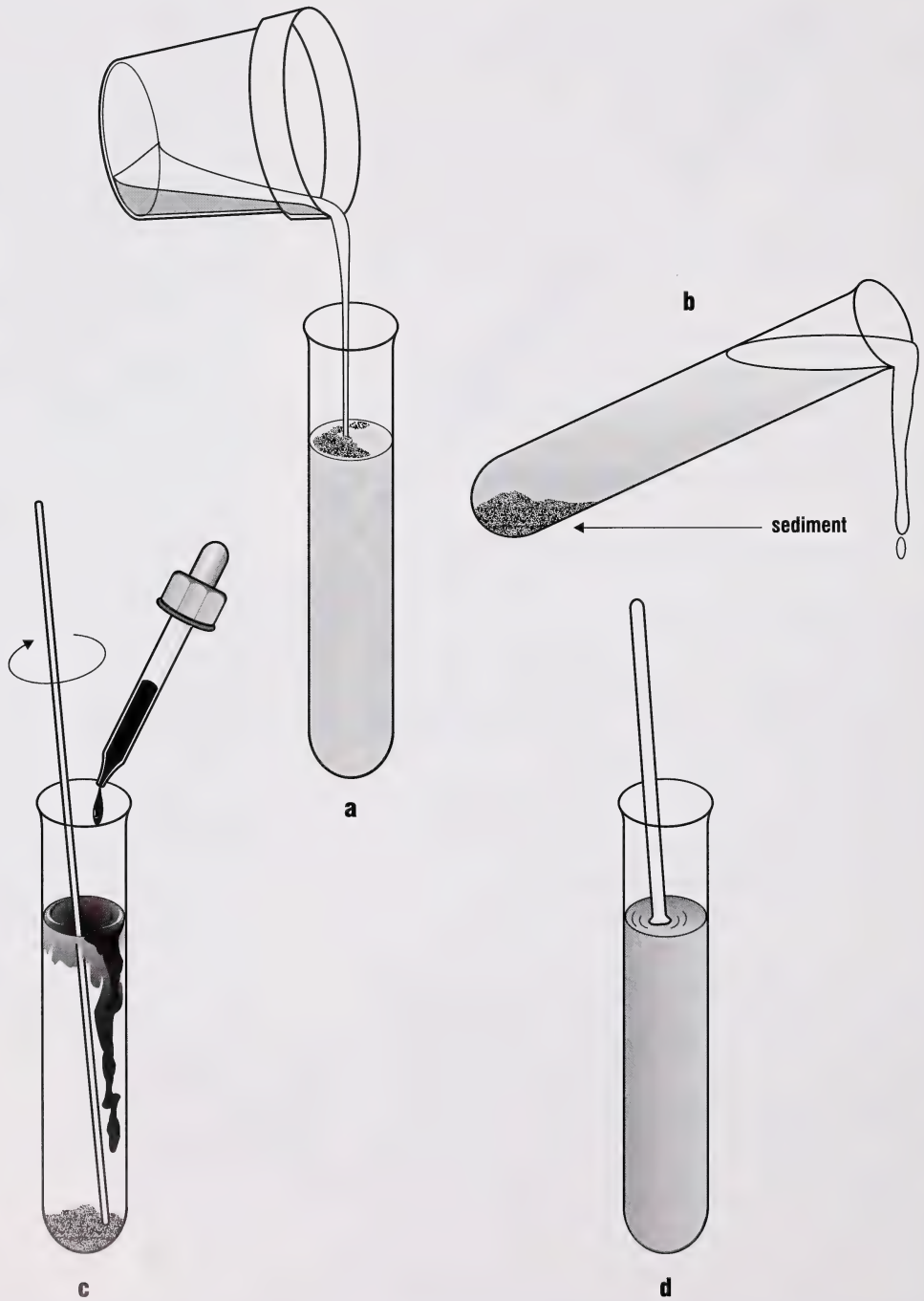
Procedure

1. Place approximately 1 teaspoon of feces in a container with 2% formalin, or refrigerate the sample in distilled water until ready for examination.
2. Mix the fecal sample thoroughly.
3. Fill a 15 ml centrifuge tube to within 1 to 2 cm of the top with the suspension (Figure 8a).
4. Centrifuge at 2300 rpm for 5 to 10 minutes.
5. Decant the supernatant (Figure 8b).
6. Add 5 to 6 drops of Lugol's solution to the sediment in the tube and mix thoroughly (Figure 8c).

Comment

The direct fresh fecal smear (DFFS) and the zinc sulphate concentration technique (ZSCT) are complimentary. Start with a DFFS (especially in diarrheic stools). Then examine negative stool samples with the ZSCT. You can include trichrome staining or air-dried PVA-preserved fecal samples as part of this routine.

Figure 8
Flotation Technique for Giardia



7. Half fill the tube with ZnSO₄ solution; mix thoroughly (Figure 8d).
8. Fill the centrifuge tube with ZnSO₄ solution.
9. Place a 22 mm square coverglass on the meniscus.
10. Centrifuge at 2300 rpm for 3 minutes.
11. Make a slide and view under medium power of your microscope.

Toxoplasma

Frenkel (1975) recommended the following procedure to isolate oocysts of *T. gondii* from cat feces or from soil. The low s.gr. (1.15) of the sugar solution floats less debris and provides a cleaner preparation. Because oocysts are small (approximately 10 μm) and shed for only one to two weeks, the chance of detecting *T. gondii* oocysts during routine fecal examination is slight (Dubey, 1994).

Procedure

1. Emulsify 1 part feces in 10 parts *Toxoplasma* sugar solution.
2. Filter the suspension through 2 layers of gauze.
3. Pour the strained feces into a 15 ml centrifuge tube.
4. Add sugar solution until a meniscus is formed.
5. Place a 22 mm square coverglass on the meniscus.
6. Centrifuge at 3000 rpm for 5 to 10 minutes. Reduce the speed slowly and remove the tubes gently.
7. Make a slide and view under low magnification (100 x), then high dry (400 x). *Toxoplasma* oocysts are best seen under high magnification.

Egg Extraction Method

(After Rossanigo and Gruner, 1991)

The efficiency of the McMaster technique is 16.5% for sheep feces compared to 95.5 to 99.5% for the Egg Extraction Method (Rossanigo and Gruner, 1991). The Egg Extraction Method is time consuming for routine diagnosis and is generally used in egg hatch assays to determine the level of anthelmintic resistance of nematodes.

Comment

Adult cats are not diarrheal when they are shedding oocysts (Dubey and Beattie, 1988).

Comment

Cattle infected with flukes [*Fasciola hepatica*] usually shed fewer than 5 eggs/g of feces. A minimum of 10 samples should be examined before a clinical impression of herd prevalence is made (Kaplan, 1994).

Comment

Fascioloides magna does not become patent in cattle and therefore cannot be diagnosed via fecal examination.

Reliably Detected

	Patant	Prepatant
Necropsy	+	+
Fecal Egg Counts	+	
Serology IHA	+	requires 2-4 weeks after infection

Procedure

1. Place 10 g of feces in a specimen cup.
2. Add 50 ml of water and mix into a paste.
3. Use a stream of water to wash the paste through 4 successive sieves (1 mm, 250 μm , 125 μm , 20 μm).
4. Collect the material from the last sieve and wash it into a flask.
5. Mix with 2 g kaolin (hydrated aluminum silicate).
6. Centrifuge for 5 minutes at 1500 rpm.
7. Decant the supernatant.
8. Mix the remaining pellet with 3 volumes of a magnesium sulphate solution (s.gr. 1.27).
9. Centrifuge for 5 minutes at 1500 rpm.
10. Pour the supernatant into a 20 μm sieve and wash the residue containing the eggs with tapwater.
11. Repeat the centrifugation with MgSO_4 3 times.
12. Transfer the eggs to a sedimentation flask, concentrate and check microscopically to determine the number of eggs by dilution (20 to 30 samples of 10 μl).

Sedimentation Procedures

Early diagnostic methods for liver flukes in cattle used sedimentation techniques (Alicata, 1941; Dennis, *et al.*, 1954, and others) that were time consuming and required large volumes of feces. Formalin ether extraction replaced these procedures for routine screening of stool samples. This technique, or its modification, the formalin-ethyl acetate extract method, detects fluke eggs, nematode larvae and protozoan cysts better than flotation methods (Faler and Faler, 1984). Fecal flotation methods are 80% effective in detecting ova and cysts, but do not recover most trematode eggs or nematode larvae (Faler and Faler, 1984).

Formalin-Ethyl Acetate Sedimentation

(After Young, 1979)

The formalin-ethyl acetate sedimentation procedure is done on fresh or formalin-fixed feces to recover trematode eggs, nematode larvae and protozoan cysts better than flotation methods. Other methods of fecal preservation may not give good results (Caroll, 1983).

Procedure

1. Mix a marble-sized piece of feces with water.
2. Filter the mixture through a tea strainer or 2 layers of dampened gauze.
3. Pour the filtered mixture into a 15 ml centrifuge tube.
4. Centrifuge at 2000 to 2500 rpm for 1 to 2 minutes.
5. Decant the supernatant.
6. Repeat steps 4 and 5 until the supernatant is nearly clear.
7. Add 10 ml of 10% buffered formalin to the sediment, and mix. Let stand for at least 5 minutes.
8. Add 3 to 4 ml of ethyl acetate, insert a stopper and shake the tube vigorously for 30 seconds. Remove the stopper carefully.
9. Centrifuge at 2000 to 2500 rpm (500 to 550g) for 2 minutes.
10. Use an applicator stick to separate the fecal debris from the side of the tube by ringing it (Figure 9a).
11. Decant the top 3 layers.
12. Swab the inside of the tube to prevent debris from running down the tube into the sediment (Figure 9b).
13. Add a few drops of formalin to the plug and mix well.
14. Use a pipette to transfer some sediment to a glass slide. Add a coverglass and examine.

Belem's *et al.*, Modification of Dennis' *et al.*, Technique for *Eurytrema*

Dennis' *et al.*, (1954) described a sedimentation procedure to detect *Fasciola* and *Paramphistomum* in cattle. Belem *et al.* (1993) modified the procedure for *Eurytrema* infections in cattle. The modification had a >94% probability of detecting

Comment

The formalin-ether sedimentation technique (Ritchie, 1948) was used for over 30 years before ethyl acetate was substituted to reduce the incendiary hazard of using ether (Young *et al.*, 1979; Garcia, and Shimizu, 1981). The formalin-ethyl acetate (FEAS) and formalin-ether sedimentation procedures give identical results (Truant *et al.*, 1981).

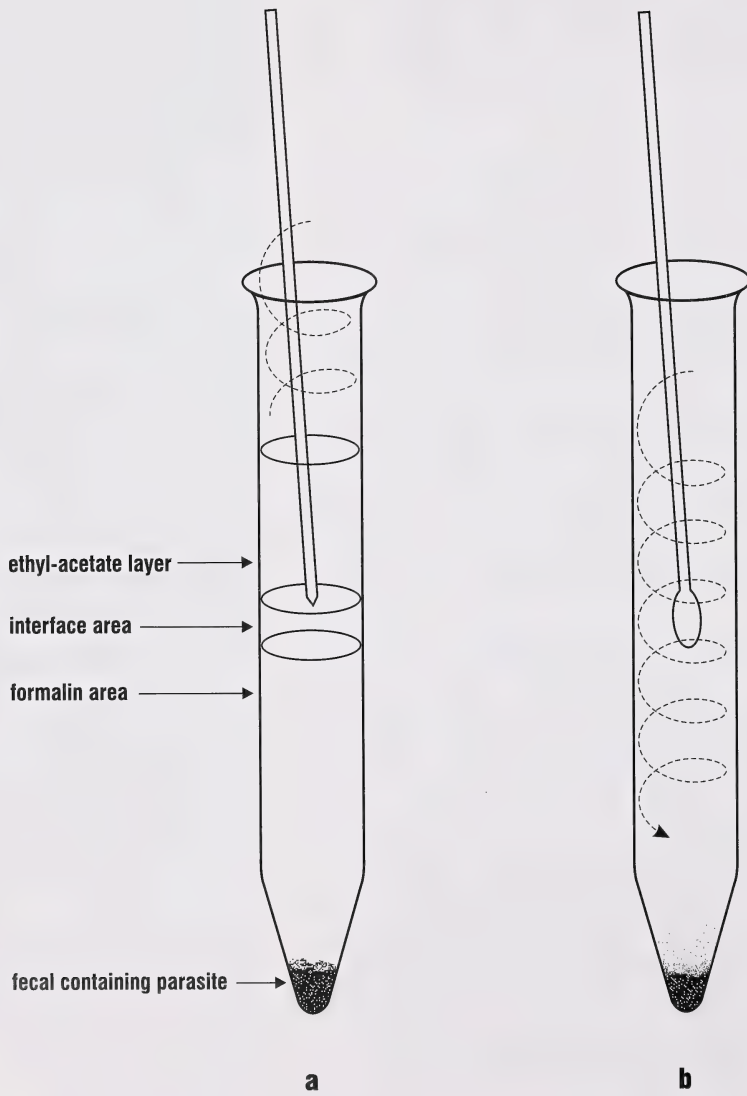
Step 1 – Use more fecal material if the sample is loose. If watery, use 10 ml of fluid feces. You could use 10% buffered formalin at this point and save the sample for later examination. If saline is used, some trophozoites can be recovered. With saline or tapwater, you must continue.

Step 3 – Use polypropylene or glass tubes. Ethyl-acetate dissolves many plastics

Step 5 – You should have 0.5 to 1.0 ml of sediment in the tube. Too much or too little sediment results in poor concentration.

steps continued on page 33

Figure 9
Formalin Ethyl-Acetate Procedure



Eurytrema infection on a single examination. Low parasite burdens and early infections have a low probability of detection, even with repeated examination.

Procedure

1. Mix 1 g of feces in 20 ml of a 0.5% detergent solution.
2. Strain through a 250 mesh/inch sieve.
3. Sediment the sieved suspension in a 125 ml conical glass.
4. Pour 40 ml of detergent solution through the sieve to wash the remaining debris. *
5. Resediment the filtrate.
6. Decant the supernatant.
7. Transfer sieved aliquots of fecal sediment to a glass slide, add a coverglass and view under 100 x magnification.
8. Examine all the sediments by aliquots.

Fecal Egg Counts – Background

Egg counting techniques are used to help determine the severity of an infection. The results of a quantitative procedure approximate the severity, but should not replace clinical examination of an animal or herd. Despite this limitation, fecal analysis provides useful information for treating individual animals, evaluating and designing parasite control programs, assessing anthelmintic efficacy (Uhlinger, 1993) or monitoring anthelmintic resistance (Martin *et al.*, 1989; Coles *et al.*, 1992). The standard for diagnosing resistance is a reduction in mean egg count of < or equal to 90% (Presidente, 1985).

Making reasonable deductions about the level of gastrointestinal nematode infections in domestic animals is essential for differential diagnosis of unthriftiness (McKenna, 1981). The relationship between eggs per gram of feces and total worm burden may not apply. Several variables influence fecal egg counts and should be considered. These and other factors result in a lack of correlation between fecal egg counts and worm burdens in cattle (Michel, 1968; Rubin, 1967; Brunnsden, 1971).

steps continued from page 31

Step 7 – The sample can be saved in 10% formalin for several years if not allowed to dry out.

Step 8 – Pressure may build up in the tube. You may get sprayed with fecal mixture if you remove the stopper too quickly.

Step 9 – This should give you four distinct layers: a base plug, a fluid layer, a solid interface layer (containing mostly fatty material) and an upper fluid layer (mostly ethyl acetate).

Step 13 – Alternatively, add a drop of methylene blue or Lugol's solution if staining is required.

*** Note**

Each sedimentation period should last 10 minutes.

Comment

- Fecal examinations should be done prior to treatment and one to two weeks post-treatment to establish the efficacy of an anthelmintic and to screen for drug-resistance.
- If the average fecal egg count is not reduced by >80%, or better >90%, drug resistant strains of the parasite may be present.
- On large farms, sample 25 to 50% of the herd and average the fecal egg counts.
- Treat again when egg counts on individuals or when 25% of a herd reaches or exceeds 200 epg strongyles or when ascarids are present (Uhlinger, 1993).

- Fecal output – affected by food intake (modified by appetite, age and body weight), diarrhea and constipation; these variables cause dilution or concentration of eggs passed (Brunsdon, 1970).
- Composition of infection – the eggs of various strongyles (except *Nematodirus* spp.) cannot be differentiated, and so the composition of the infection cannot be determined. Seasonal changes in species (genus) composition of the numerically dominant species may also occur. Therefore, egg counts obtained at different seasons may be the result of infections of markedly different composition and perhaps pathogenicity (Brunsdon, 1970).
- Host resistance – fecal egg counts in older animals may be deceptively low in relation to worm numbers. Host immunity may affect parasite egg production. This may vary from partial to complete, and may have a different effect on different genera present, being greatest in *Nematodirus* followed by *Ostertagia* and *Cooperia* (Kloosterman, 1971).

Coyne *et al.*, (1991) demonstrated that the fecal egg count for *Nematodirus* spp. in lambs is linearly related to worm burden when intensity of infection is <6,500 worms/lamb. The relationship between egg and worm burden is linear for *Haemonchus contortus*. A total worm count from the gastrointestinal tract is still the most reliable means of determining the species and number of parasites present.

Significance of Fecal Egg Counts

A zero fecal egg count does not indicate the animal is parasite-free. There are several causes for a low or zero egg count. Clinical signs may be associated with pre-adult, non-egg-laying stages of the parasite. A zero egg count suggests that all is well and the animal's environment is not being contaminated by large numbers of ova. Repeated negative examinations are needed to assure that the individual or herd is not currently harbouring parasites. A positive egg count reflects the rate at which the animal acquires infection and the degree to which it is contaminating its environment with nematode eggs. The infective potential of these eggs

depends on climatic and seasonal variation and pasture management factors (Uhlinger, 1993).

Total egg counts of mixed infections do not give a true indication of the level of infection because the egg laying capacity and pathogenicity of each species differs. Species composition may vary from region to region or from season to season. A particular count in one area or season may not mean the same thing as the same count in another area or season.

Species Variations

Bovine

Fecal egg counts in cattle are low compared to other species. Significant egg counts are set somewhat arbitrarily. Some laboratories use a figure of 500 egg, while others use as low as 200 egg (Michel, 1968).

Sheep

The interpretation of an individual egg count in terms of the probable size and pathogenicity of the worm burden is affected by the age of the infection and by the immune status of the host. The age of the infection is important because in acute outbreaks, disease may occur before most of the parasites mature to the egg-laying stage (Brunsdon, 1970). In *Nematodirus* infections, larval stages appear to be more pathogenic than adults (McKenna, 1981). This, along with the fact that species of *Nematodirus* produce few eggs, suggests that limited reliance should be placed on egg counts for diagnostic purposes (McKenna, 1981). Host immunity may suppress the parasite egg production either completely or partially, and its effect on various genera may differ. Conversely, if immunological suppression of egg production is released (e.g. post-parturient rise), high egg counts may result from light worm burdens (Brunsdon, 1970).

Coyne *et al.*, (1991) estimates for the fecundity of some nematodes of sheep are in agreement with those of Gordon (1967), except for *Oesophagostomum* (Table 2).

Table 2.
Approximate fecundate (eggs/
female/day) of some
trichostrongylid nematodes of
sheep.

	Mean (eggs/female/day)	
	Coyne <i>et al.</i> , (1991)	Gordon (1967)
<i>Haemonchus</i>	6,582	5,000 to 10,000
<i>Chabertia</i>	3,000 to 5,000	–
<i>Oesophagostomum</i>	11,098	3,000 to 5,000
<i>Ostertagia</i>	100 to 200	–
<i>Trichostrongylus</i>	262	100 to 200
<i>Nematodirus</i>	40	50

Comment

Fecal consistency affects egg counts; correction factors of 0.5 for constipated or starved animals; 1.0 for normal feces (pellets); 1.5 for soft pellets and soft formed stools; 2.0 for soft unformed stools; 2.5 or 3.0 for very soft (mushy to thick liquid) stools and 3.0 to 4.0 for diarrheic (liquid) stools should be used (Gordon, 1967; Levine and Clark, 1956; Levine, 1980).

The fecundity of the parasite appears to remain constant regardless of parasite intensity or duration of infection (Coyne *et al.*, 1991). Also, parasite fecundity remains unchanged throughout the grazing season.

Horses

Horses are infected with large and small strongyles. Small strongyles usually comprise 85 to 100% of the total worm burden (Uhlinger, 1993). Some strongyles have prolonged prepatent periods (up to 11 months for large strongyles). Small strongyles may be patent in as few as 40 days.

Cats and Dogs

Cats and dogs can carry adult *Echinococcus*. Eggs of *Echinococcus* spp. are indistinguishable from other *Taenia* tapeworms, including those common to dogs and cats (e.g. *Taenia pisiformis*, *T. taeniaeformis*). The similarity makes diagnosis difficult, especially when mixed taeniid infections are involved.

Echinococcus should be suspected in a dog or cat that is shedding taeniid eggs and not *Taenia* proglottids. Infection with *Echinococcus* is confirmed at necropsy or by purging the animal and examining the intestinal contents for worms. Purging should be done in an area that can be decontaminated. Not all infected dogs will pass worms. Evacuations of intestinal contents should be filtered through a fine mesh sieve (pore size of 300 μm or less) and the retained material examined for *Echinococcus* adults. *Echinococcus multilocularis* is small (1.5 to 4.0 mm) and difficult to see without a stereomicroscope.

Baermann Procedure

Baermann (1917) developed his procedure to recover hookworm larvae from soil samples. The technique was redescribed by Cort *et al.*, (1922) and subsequently modified to recover nematode larvae from soil, herbage, fecal samples and tissue digest. Some modifications were designed to recover specific parasites, like *Parelaphostrongylus* (Samuel and Gray, 1982).

Most laboratories use the Baermann technique to detect lungworm larvae (*Dictyocaulus*) or *Strongyloides* spp. in feces.

The best results are achieved when 20 to 40 g of feces are placed on 2 layers of gauze supported by a galvanized screen suspended in a 7 to 10 cm diameter funnel (Todd *et al.*, 1970). The apparatus is filled with warm tapwater (20 to 25°C) and left to stand for six hours or overnight if few larvae are present (Georgi, 1980). Samples left longer than 24 hours may contain larvae from intestinal nematodes complicating the diagnosis.

Extracting nematodes from feces depends on animal movement. Non-motile or slow-moving animals limit the effectiveness of the Baermann method. Although the Baermann method is used routinely in veterinary parasitology diagnostics, we know little about the behaviour of the larvae we are attempting to extract.

Procedure

1. Clamp the rubber tubing and pour warm water (20 to 25°C) into the funnel until the water level is about 2 cm above the wire screen.
2. Remove trapped air bubbles in the neck of the funnel by loosening the clamp and allowing a little water to run out.
3. Place 2 layers of gauze over the wire screen.
4. Place 20 to 40 g of well-mixed feces on the gauze. The water should just cover the sample.
5. Place filter paper over the mouth of the funnel.
6. Allow the apparatus to stand for 4 to 6 hours or overnight (Figure 10).
7. Loosen the clamp and collect 15 ml of fluid in a tube. Concentrate larvae by centrifuging the fluid prior to scanning.
8. Pour into a small, gridded petri dish and view under medium to high magnification of the stereomicroscope.

Comment

Lungworm Larvae in Feces

Use fresh fecal material. Unrefrigerated fecal samples older than 24 hours may contain other nematode larvae. Fecal samples taken off the ground may contain free-living nematode contaminants.

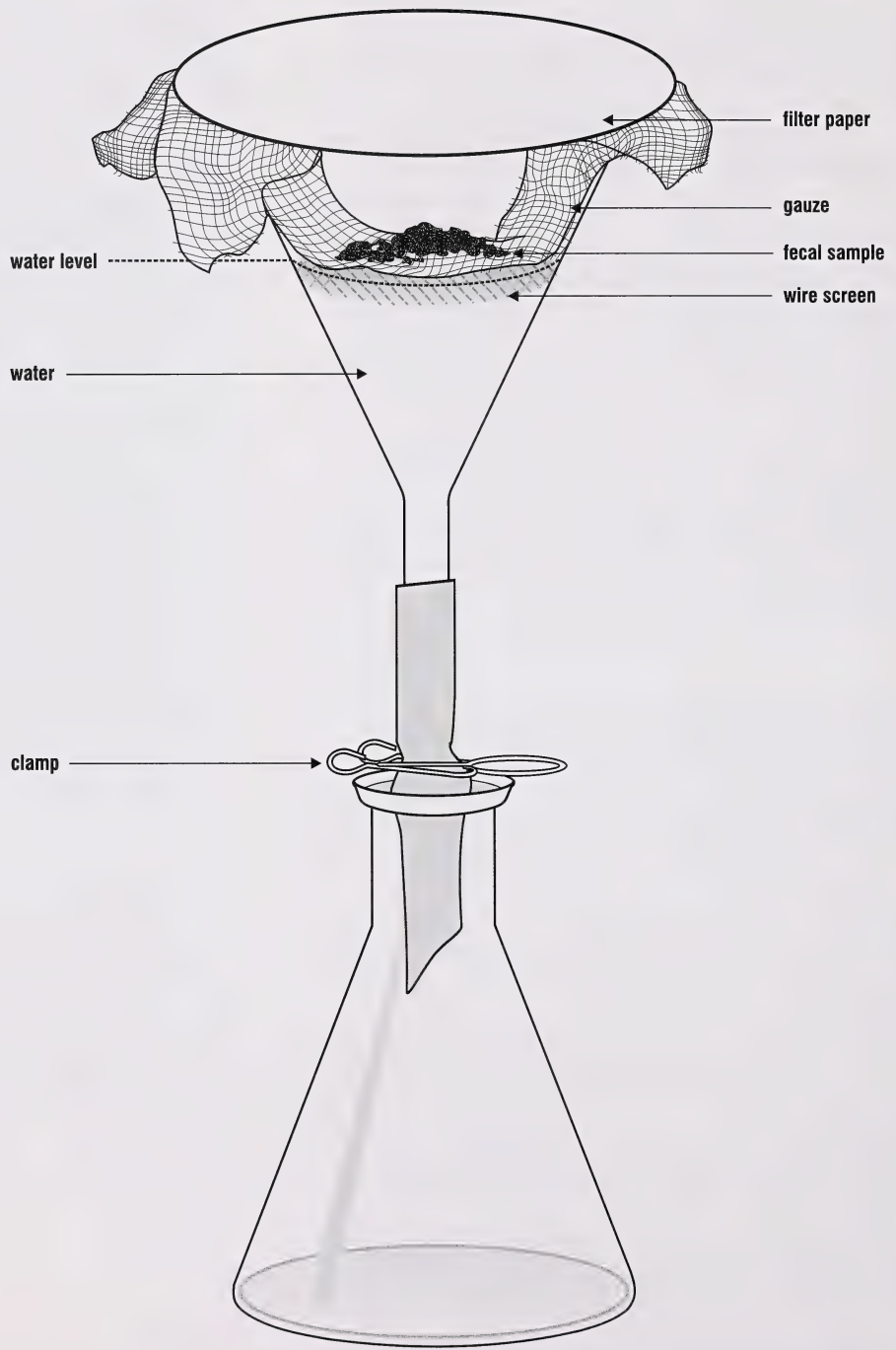
Comment

Larvae of *Parelaphostrongylus tenuis* can contaminate the glassware used in the Baermann technique despite rigorous cleaning (Whitlaw and Lankester, 1995). To clean the glassware, flush the apparatus with hot or cold water, then immerse it in 95% ethanol.

Comment

The Baermann technique is not reliable for *Filaroides hirthi* from dog feces. Zinc sulphate flotation is recommended (Georgi *et al.*, 1977).

Figure 10
Baermann Apparatus



Culturing Nematode Larvae

There are several methods to collect infective nematode larvae. The techniques involve a two-step procedure of culturing nematode eggs in aerated feces, followed by isolating the larvae. The method described by Pullan and Sewell (1981) is reliable and convenient to use in the laboratory.

Procedure (After Pullan and Sewell, 1981)

Culturing

1. Add Vermiculite to 200 to 500 g of cattle feces. Mix well.
2. Wrap the mixture in 1 layer of absorbent gauze.
3. Place the wrapped feces on a screen platform in a plastic box.
4. Incubate the sample at approximately 23°C for 15 days. *Nematodirus* will take up to 19 days to develop.
5. Open the gauze and stir the mixture every second day to break up the growth of fungi and aerate the mixture.

Extracting

1. Flood the box with warm water, completely covering the feces.
2. Let the box stand undisturbed for 6 hours.
3. Remove the gauze from the box and discard the fecal mixture.
4. Pour the fluid remaining in the box into a Baermann funnel.
5. Let the funnel stand overnight to allow the larvae to sediment.
6. Draw off approximately 15 ml of fluid and examine for larvae.

Comment

Fecal material should be kept moist, not wet. Add vermiculite or water to adjust moisture.

Comment

Ostertagia develops better when it is kept at lower (e.g. 23°C) temperatures for a longer period (15 days) than when incubated at higher temperatures for a shorter period (Pullan and Sewell, 1981).

Comment

A representative sample of at least 100 larvae should be identified.

Henriksen-Korsholm Method

1. Mix 5 to 8 g of feces with demineralized water (max. 10 ml) until a suitable soft consistency is attained. Liquid or watery feces do not require additional fluid.
2. Mix in 2 to 3 g of vermiculite to give the culture an ideal consistency. Adjustment moisture adding water or vermiculite as required.
3. Cut a polystyrene cup into 2 pieces and transfer the fecal culture to the bottom half. There should be 4 or 5 perforations in the bottom of the cup (Figure 11a). Cover the mouth of the cup with a double layer of gauze.
4. Insert the bottom half of the cup containing the covered culture into the top half of the cup (Figure 11b).
5. Incubate the culture in a moisture box (Figure 11c). The culture should be suspended 1 to 2 cm above the bottom of the box that has been lined with moistened filter paper.
6. Incubate at room temperature for 10 to 12 days or for 7 days at 27 to 28°C.
7. Transfer the culture chamber to a conical glass vessel filled with tapwater (20 to 25°C).
8. Let stand in a Baermann-like apparatus for 24 hours at room temperature. The larvae will migrate through the gauze and settle at the bottom of the glass vessel. To collect the larvae, pipette off 0.2 to 0.4 ml of the deposit.

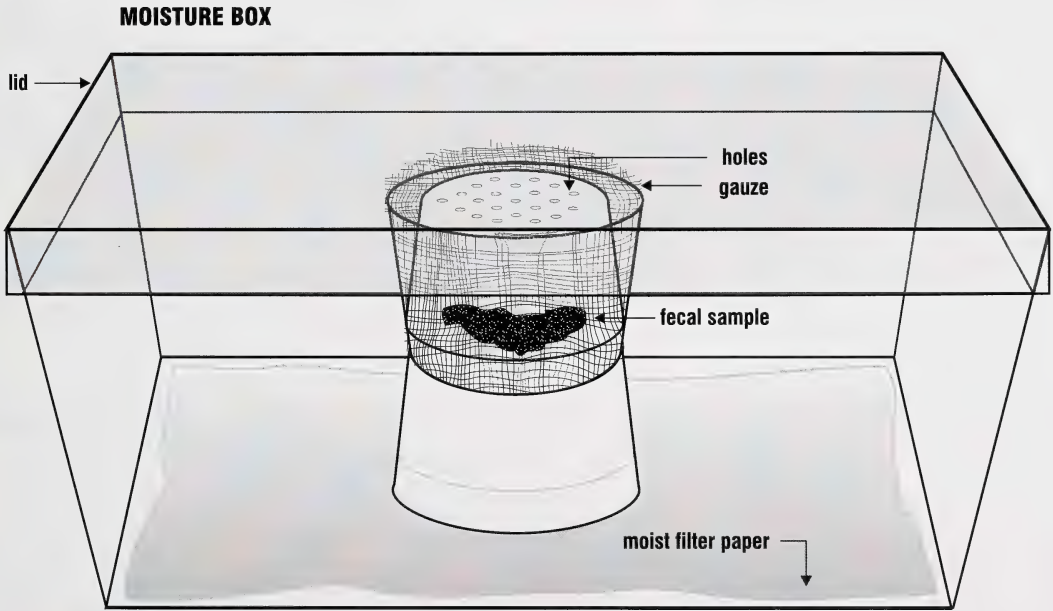
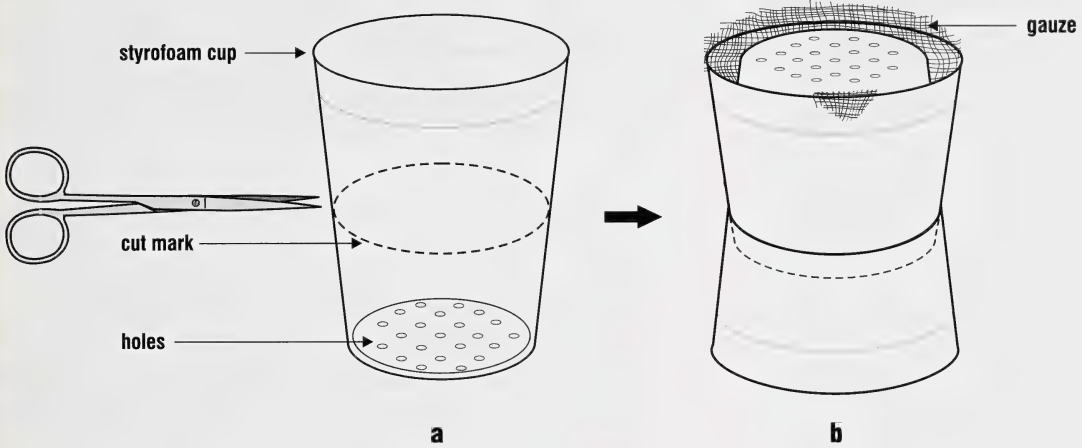
Separating Free-Living from Parasitic Nematode Larvae

Free-living nematodes contaminate fecal samples taken off the ground. The free-living forms are killed when placed in an acidic solution. Parasitic larvae remain active and are easily sorted out.

Procedure

1. Use the Baermann technique to collect nematode larvae.
2. Place larvae in 3% acid solution.
3. The free-living larvae die quickly, but the parasite larvae remain active.

Figure 11
Henriksen-Korsholm Method



c



transfer to Baermann apparatus

* **Note**

Trichostrongyle larvae are stained red while most free-living nematodes are decolourized.

Staining Method

Alternatively, separate free-living from parasitic larvae by adding one or two drops of Lugol's solution to a slide or vial containing the larvae. Free-living nematodes absorb iodine and appear orange, while parasitic larvae do not absorb the iodine.

Large samples in petri dishes can be stained and counted as follows:

1. Add a few drops of Lugol's iodine solution to your counting dish.
2. Let stand for approximately 1 hour.
- * 3. Add a few drops of thiosulphate solution and mix.

The Skin



Introduction

Ticks, lice and fleas can be seen with the unaided eye. Smaller mites (e.g. *Cheyletiella*, *Otodectes*) require a hand lens or stereoscopic microscope to be seen. Burrowing mites are found in deep scrapings taken from lesions and examined microscopically.

Postmortem

Visually examine the suspected area (skin, feathers, hair). Collect several specimens of each ectoparasite and preserve them in 70% ethanol. Scrape lesions and suspect tissues. Make a wet smear of the scraping and examine under low magnification (100 x).

Scrapings

Take scrapings from an area containing part of the transitional zone between lesions and normal tissue. Place scrapings in a container with mineral oil or glycerine to prevent the sample from drying.

Portions of skin containing lesions bordered by “healthy” tissue should be placed in air-tight plastic containers and refrigerated until examined (within 24 to 48 hours). Preserve a similar piece in 10% formalin.

Mites

Scraping for Mites

1. Place a drop of mineral oil on a scalpel blade.
2. Scrape the area at the periphery of a lesion until blood oozes from the lesion. Choose two active lesions.
3. Transfer the scraped material to a microscope slide and add a coverglass.
4. If the scraping contains much hair and crusty material, add a few drops of 5 to 10% KOH before adding the coverglass, and let stand for 10 to 20 minutes to dissolve the material.
5. View under low power (40 x) of your compound microscope.

Comment

- Examine scrapings from several areas.
- If necessary, clip the hair to expose the skin.
- Scrape the skin in the direction of the hair.
- When obtaining samples from the head, always scrape away from the eyes.

Comment

Prolonged boiling in KOH will disintegrate the mites.

Comment

Demodex spp. are transparent, so reduce the light to increase contrast.

Concentrating Mites

Deep-burrowing mites (e.g. *Sarcoptes* sp.) are difficult to collect. You may have to pool the scrapings from several lesions. Digest the scraping in KOH and concentrate the mites using Sheather's sugar solution.

Procedure

1. Place the scraping in a glass centrifuge tube.
2. Add 5 to 10 times the volume of 5% KOH.
3. Heat the mixture in a water bath until the hair and crusty material has dissolved (about 5 minutes).
4. Pour 5 ml of Sheather's sugar solution into a 15 ml centrifuge tube and let cool.
5. Add 5 ml of Sheather's sugar solution and mix well.
6. Add sugar solution to a level just below the top of the tube.
7. Centrifuge at 1500 rpm for 3 minutes.
8. Gently touch the surface of the solution with a flat-ended glass rod and place the drop of fluid obtained on a microscope slide.
9. Add a coverglass and view under a compound microscope.

Demodectic Mites

Demodex spp. live in skin pustules or hair follicles. Examine sebum (the oily secretions of sebaceous glands) or caseous material expressed from pores or pustules under the microscope.

Procedure

1. To express the material, gently pinch the skin between the thumb and forefinger.
2. Place the expressed material on a microscope slide.
3. Add a drop of mineral oil.
4. Apply a coverglass and view under the compound microscope.

Ticks, Lice, Fleas and Keds

Examine large ectoparasites immediately or store them in 70% ethanol. Ethanol heated to the point of steaming will help prevent specimens from curling.

Hoyer's Solution

Small arthropods are placed in Hoyer's solution. Specimens are fixed, cleared and mounted in one step. Fresh specimens or material previously fixed in 70% ethanol can be mounted in this way. The cuticle can be stained by adding a small amount of Chlorazol black or Lignin Pink to the mountant.

Procedure

1. If large specimens are filled with blood, puncture their cuticle with a fine needle and place them in boiling lactic acid for a few seconds.
2. Place either fresh or fixed specimens on a microscope slide.
3. Cover with a few drops of Hoyer's solution and add a coverglass.
4. View under the microscope.

Beneath the Skin

Myiasis

Diagnosis presents little difficulty because larvae are large. Remove the larva or entire nodule surgically and place in a container. Refrigerate or preserve the larva or excised tissue in 10% formalin until examined.

Examine the larva and record any diagnostic features. Remove the spiracular plates (Figure 12) and place them in Hoyer's solution for detailed examination.

Cuterebra

The larvae occur in subcutaneous nodules of several mammals, particularly rabbits and wild rodents, and can occur in dogs and cats.

Hypoderma

Look for subcutaneous swellings (warbles), particularly along the back of cattle.

Screw worm

Cutaneous myiasis from larvae of the screw worm fly, *Cochliomyia*, is detected by finding the larvae in wounds, urine-soaked matted coats, or in burrows or tracts in the skin. Examine affected areas particularly around the eyes, nose, mouth and perineum.

Nematode (*Onchocerca*)

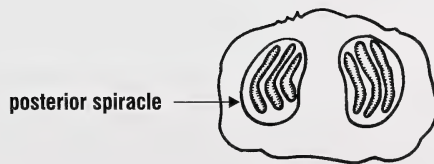
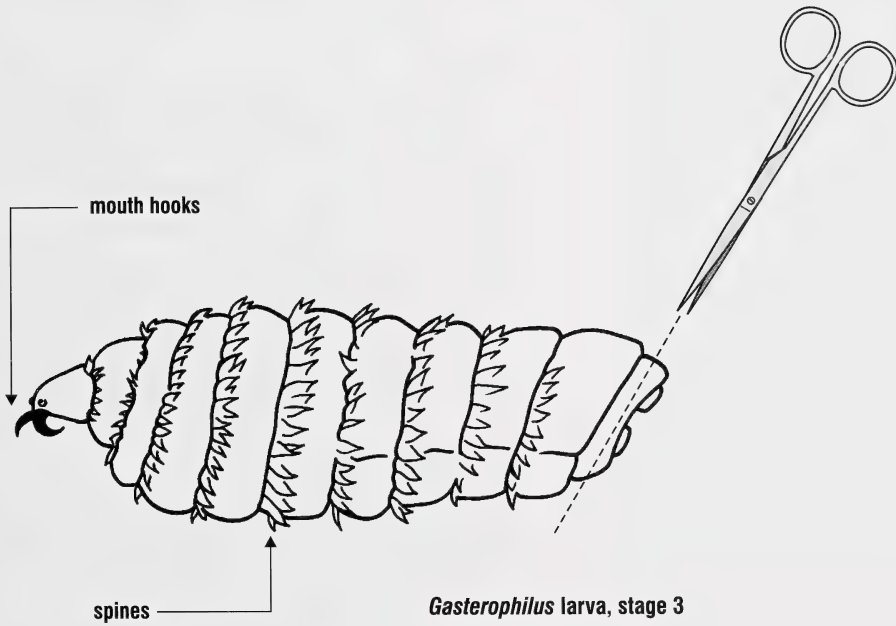
Antemortem

Place skin biopsies in 5 ml of physiological saline. Samples should be taken from several sites. At least one sample should be placed in 10% formalin for histological examination.

Postmortem

Look for adults in connective tissues surrounding ligaments or microfilariae in skin biopsies. Microfilariae may occur in histological sections or deep skin scrapings. Remove a 2 cm²

Figure 12
Removing Spiracular Plates





Comment

Sodium azide inhibits the growth of microorganisms.

sample of skin from the ventral midline of the abdomen where microfilariae are most numerous. Place half the sample in 10% formalin and the other half in physiological saline. Tissues should be examined immediately, or refrigerated or preserved in 10% buffered formalin and examined later.

Diagnostic

Look for microfilariae in fresh or fixed biopsy material. Macerate fresh tissue samples and soak them for one to two hours in saline at 37°C. Examine the sediment for microfilariae or add 10% buffered formalin, and after 30 minutes, examine a wet smear of the sediment. The solution can be centrifuged before making a wet smear. *Onchocerca* microfilariae must be distinguished from microfilariae of *Setaria*, and *Parafilaria*. Fresh tissues can be macerated and digested in pepsin, and the larvae concentrated by centrifugation.

Collagenase Digest

(After Schulz-Key and Karam, 1984)

Adult *Onchocerca* sp. can be isolated from fresh (Schulz-Key, 1978) or ethanol-fixed biopsies (Schulz-Key and Karam, 1984) by digesting the surrounding host tissue using collagenase. Collagenase produces better results than pepsin or papain.

Procedure

1. Wash the ethanol-fixed biopsy in several changes of phosphate-buffered saline (PBS) for 24 hours.
2. Transfer the biopsy to 0.1 or 0.3% collagenase solution in PBS containing 0.01% sodium azide.
3. Incubate biopsy in collagenase at 35°C for 2 to 7 days.
4. Place the digested biopsy in a petri dish and use dissecting needles to tease the tissue apart. This is best done using a stereomicroscope.

Muscle

Introduction

Several parasites occur in muscle tissue. Tapeworm cysts occur in cattle (*Taenia saginata*), swine (*T. solium*) and sheep (*T. ovis*). Nematode larvae (*Trichinella* sp.) or protozoan cysts (*Sarcocystis* spp.) occur in many animals.

Taenia saginata

The heart, masseter muscles, tongue, oesophagus and diaphragm have more cysts than elsewhere in the carcass. Light infections are difficult to detect.

T. solium

Skin the carcass and examine the muscle grossly. Make several cuts into the muscle, particularly the masseter. Remove portions of the tissue containing cysts. Preserve the tissue in 10% formalin if it cannot be examined fresh or refrigerated.

Squash preparations of cysts may reveal the presence of hooklets or the characteristic scolex of a tapeworm.

Trichinella spp.

Trichina (larval stage in muscle) is detected by trichinoscopy or a digest method. The digest method is more reliable when infections are light. Either technique may not detect recent infections (<3 weeks in duration) or light infections, e.g. <0.2 larvae/g (Oliver *et al.*, 1988).

Procedure

1. Macerate 20 g of tissue. *
2. Digest in 1% pepsin plus 0.5% HCl for 12 hours at 37°C.
3. Dilute the digest to twice its original volume.
4. Refrigerate for 2 hours.
5. Filter through a Baermann funnel loosely packed with gauze.
6. Place the filtrate in a funnel for 2 hours to allow the larvae to settle.
7. Collect 100 ml and dilute with 100 ml tapwater.

Comment

Sarcocysts are best detected on histological examination.

* Note

For pooled samples, use 60 g of tissue/100ml digest solution.

8. Refrigerate for 2 hours.
9. Centrifuge at 6000 rpm for 10 minutes.
10. View the sediment under a microscope.

Intestine

Introduction

Feces or portions of intestine are routinely examined when intestinal parasitism is suspected.

Protozoa

Protozoa (excluding coccidia)

Examine a wet smear of feces for motile protozoa. Record any characteristic movement of the protozoa. Add Lugol's stain and re-examine the slide. Follow this preliminary examination with a concentration technique to detect cysts. Permanent stained slides reveal more protozoan parasites than wet mounts or concentration methods (Garcia *et al.*, 1979), and we recommend you make them routinely.

Preserve diarrheic fecals in polyvinyl alcohol (PVA) and use the formalin ethyl acetate procedure to concentrate parasites. PVA preserves trophozoites and cysts of protozoa that retain their stainability for some time. Permanent staining cannot be made from formalin-fixed feces. Iodine will stain protozoan cysts if formalin preservation was used.

Coccidia (excluding *Cryptosporidium*)

Look for oocysts in feces. Fecal samples should be examined with a concentration technique (e.g. Sheather's). If quantitative measures are required, the McMaster's Technique or Modified Wisconsin is recommended. When checking for coccidia, remove approximately two tablespoons (more if diarrheic) of feces from the colon. Portions of tissue can be cut from inflamed areas and examined. Tissues and fecal material should be refrigerated or preserved (10% formalin) until examined.

Damage to the intestine may occur before oocysts develop. Stages that develop within the mucosa may be detected by examining smears from mucosal scrapings or from histological preparations.

Table 3
Staining *Cryptosporidium*

Stain	Colour	
	Oocysts	Yeast
Kinyoun acid-fast	Red	Green
Iodine	Colorless	Brown
Giemsa	Purple	Purple

Cryptosporidium

Diagnosing *Cryptosporidium* is done by finding oocysts in the feces or by histological examination of infected tissue at necropsy. Smears of the tracheal or intestinal mucosa should be stained to aid identification (Table 3).

Nematodes

Microscopic examination of feces from the colon or rectum will detect many nematode species. The McMaster's or Modified Wisconsin Technique is recommended.

Postmortem

Large nematodes (*Haemonchus* spp., *Toxocara* spp., etc.) are visible in the opened intestine. Smaller worms (*Ostertagia* spp., *Trichostrongylus* spp.) are difficult to see during postmortem examination. Remove debris by passing the intestinal contents through a series of sieves and examining the material retained on the finer meshed screens. Use a dark background with back illumination to see the worms. Pepsin digest of the abomasal mucosa (Brunsdon, 1970) will detect PreType II infections, inhibited early fourth stage *Ostertagia ostertagi* and late fourth and fifth stage worms (including *Trichostrongylus axei*), many of which are overlooked if only abomasal contents are examined (McKenna, 1976).

In horses, the stomach should be palpated for nodules caused by *Draschia megastoma*.

Tapeworms

Examine feces grossly for proglottids. Clean proglottids in tapwater before fixing in 10% formalin (or 70% ethanol) and process them as you would whole mounts.

Arthropod Larvae

Remove *Gasterophilus* larvae from the stomach and preserve them in 70% ethanol.

Total Worm Count

To evaluate the role of parasitism in disease, both the specific parasite(s) and their numbers must be determined. Several factors influence the number of parasites required to produce disease. Larger numbers of intestinal nematodes are required to cause disease in adult cattle than in calves less than one year of age. Malnourished or stressed animals may succumb to fewer parasites (Jordan and Stair, 1984).

Egg counts are used to estimate the number of worms present in the intestine. However, nematodes do not release eggs at a constant rate. Severe damage may occur from heavy worm burdens undetected by quantitative fecal analysis. It is desirable to determine the total number of worms present during necropsy.

Procedure

1. Remove the abomasum and open along its entire length.
2. Flush the contents into a container and add 500 to 1000 ml of 10% formalin. *
3. Let the tissues fix for at least 1 hour.
4. Pour through a set of decreasing-sized sieves.
5. Rub the mucosa briefly to remove adherent parasites, then rinse and add the washings to the bucket.
6. Wash the sieves several times with tapwater.
7. Place the sieved contents into a separated bucket.
8. Add water to make 4 liters.
9. While mixing, remove a 40 ml sample from the bucket, place in a petri dish and count the worms present.
10. Multiply the count by 100 to obtain the total number of worms present.

Mucosal Scraping of Abomasum

In type II ostertagiasis (winter ostertagiasis) in cattle and sheep, the larvae remain in abomasal glands and are not detected using regular procedures. The mucosa must be scraped and tissues digested in a pepsin-HCl solution prior to

Comment

Three major factors influence the size of worm burdens in individual hosts or host groups (Parsons, 1994):

- i. spatial discontinuity in the distribution of infective stages of the parasites in the environment.
- ii. heterogeneity of host behaviour.
- iii. genetic and other determinants of host resistance.

* Note

This reduces the formaldehyde concentration to about 5% thus reducing unpleasant effects upon the workers. In practice, 5% formal saline is often added to large volumes of ingesta in water, thereby reducing the concentration by about half.



Comment

**Step 6 – Adding formalin
stops the digest action.**

screening. The larvae of large and small strongyles within the intestinal mucosa of horses can be detected using this technique.

Procedure

1. Scrape the mucosa with a dull knife or scapel.
2. Digest the scrapings in a pepsin-HCl solution.
3. Incubate at 37°C for 4 to 6 hours, stirring periodically.
4. Pass through 2 wire screens. Use a #8 aperture for the upper and a #40 for the lower screen. Wash the screens with a gentle stream of water.
5. Collect the larvae and examine under a dissecting microscope.

Swabs

Swabs should be taken and examined immediately or soaked in a culture medium. When the swabs are taken, two smears should be made and fixed in Schaudinn's fixative or 70% ethanol.

Digest Procedures

Digesting the abomasum or stomach in pepsin-hydrochloric acid is the usual method for recovering nematode larvae from these tissues. Incubating tissues in saline is efficient, and searches are easier and quicker (Jackson *et al.*, 1984).

Procedure

Pepsin-HCl Digest

1. Open the stomach and remove the contents.
2. Wash the mucosa gently under running tapwater.
3. Cut the stomach into 10 ml square pieces.
4. Place the stomach pieces into a beaker containing pepsin digest fluid.
5. Incubate at 37°C until the mucosa is digested (about 2 to 4 hours).
6. Add an equal volume of 10% formalin.

7. Fix the sample for 16 to 24 hours.
8. Strain and wash the fixed material through a 1 mm aperture sieve.
9. Allow the material to settle (follow Steps 5 to 11 of the upcoming Sedimentation Procedures), then examine.

Procedure

Saline Incubation

1. Remove the abomasum.
2. Open the abomasum along its lesser curvature.
3. Rinse the mucosa with tapwater and collect all sediment.
4. Place the abomasum in a bucket containing physiologic saline at 37°C.
5. Shake or stir the contents periodically during incubation in saline at 37°C for 4 hours.
6. Remove the abomasum and rinse it in fresh saline. Discard the abomasum.
7. Add the rinsed material to the contents of the incubated material.
8. Fix the solution with formalin.
9. Do worm counts.

***Ollulanus tricuspis* in Cats**

This small nematode lives on the gastric mucosal surface, under the mucus, or partially embedded in gastric glands. These viviparous parasites are not visible grossly, and the larvae are not passed in the feces.

Antemortem Diagnosis

(After Hargis *et al.*, 1983)

1. Induce vomiting (e.g. By a 2.2 mg/kg xylazine intramuscular injection).
2. Collect the vomitus.
3. Filter the vomitus through a tea strainer with apertures of approximately 1 mm.
4. Examine the filtered fluid using a dissecting microscope.

Comment

When the stomach is filled, it may take several days of repeated sedimentation to remove enough debris to allow easy examination of the sample.

Microscopic examination of vomitus is adequate in heavily infected cats. However, repeated dilution and sedimentation of the stomach contents and mucosal washings is the best method for detecting *O. tricuspis*.

Sedimentation Procedures

Examine stomach contents or washings of stomach mucosa with a dissecting microscope. The sedimentation procedure is more reliable than the pepsin-HCl method (Guy, 1984).

Procedure

1. Open the stomach by cutting along its greater curvature and empty the contents into a 1 liter jar.
2. Wash the mucosa thoroughly under running water and collect the washings. Add sodium bicarbonate to break up excess mucous.
3. Filter contents through a 1 mm aperture sieve.
4. Add an equal volume of 10% formalin to the sample and let stand for 16 to 24 hours.
5. Decant the supernatant and save the sediment.
6. Add tapwater and allow to settle for 1 to 2 hours.
7. Repeat steps 5 and 6 until the supernatant is fairly clear.
8. After the final sedimentation, transfer the residue to a graduated petri dish.
9. Add a few drops of Lugol's solution to the sample and let stain for 3 to 5 minutes.
10. Decolorize the background with 10% sodium thiosulphate solution.
11. Examine the sample with a dissecting microscope at approximately 40 x.

Mural Transillumination Technique

Reinemeyer and Herd (1986) demonstrated that the mural transillumination technique (MTT) was superior to mucosal digestion for larvae encysted in the large intestine of horses.

During their study, the numbers of larvae recovered by pepsin-HCl digestion for three and six hours were significantly lower than were the numbers determined by MTT. The pepsin-HCl digestion technique was originally developed to recover *Trichinella* larvae from muscle tissue, then modified to quantify nematodes in the abomasal mucosa.

The Eye

***Thelazia* sp.**

Procedure

Remove the entire eye and associated tissues, including the skin surrounding the orbit, the upper and lower eyelids and the lacrimal glands.

Use a 2.5 x Optivisor viewer to examine the conjunctival surfaces, the cornea, the area beneath the nictitating membrane and the hair around the eye. Apply digital pressure to the base of the lacrimal ducts to expel worms from these sites. Cut the lateral canthus and evert the eye. Apply finger pressure to the gland of the nictitating membrane.

After dissection, place each eye and its associated tissues into a one liter plastic bucket with sufficient tapwater to cover the eye. Soak the eye at room temperature for 24 hours, then re-examine the eye and fluid in the container.

The Mouth

Examine the tongue, pharynx, oesophagus, and gums for lesions or migrating larvae.

Protozoa may be common in the mouth of primates and occasionally occur in birds, dogs and cats. Collect scrapings or swabs to detect *Entamoeba* sp. or *Trichomonas*. Material obtained by mouth scraping should be placed in a clean, airtight container. The material can be removed from the swab or container and examined.

Examine a wet smear of the swabbed material. Permanent stains (e.g. Kohns' or Giemsa's stain) may be used to aid identification.



Lungs

Nasal Passages – Sheep

Postmortem

Saw the sheep skull in half along its length. Remove the nasal septum and open the sinuses to expose larvae of *Oestrus ovis*.

Diagnostic

Use Hoyer's mounting fluid to make permanent mounts of the spiracular plates of the larvae.

Trachea and Bronchi

Postmortem

Lungworms are found in varying numbers in the respiratory passages. Remove part of the trachea or bronchi containing several parasites, or the parasites themselves, and place them into a plastic cup. Keep the specimens moist until examined. If the material cannot be examined within one or two days, preserve it in 10% formalin.

Diagnostic

Diagnosis is made by observing the adult nematode in the lungs or trachea. Lungworms can be cleared in glycerine and identified. Live nematodes are transparent enough to see internal details of their morphology if placed in a drop of water on a slide.

There are several methods of perfusing lungs to recover lungworms (Inderbitzen, 1976; Oakley, 1980; Eysker *et al.*, 1990; Andrews and James, 1994). These methods are generally time consuming.

Procedure

1. Remove the intact respiratory system with the heart attached.
2. Make a small incision in the pulmonary artery.



3. Connect one end of a rubber tube to a cold water tap and insert the other end of the tube through the incision into the artery.
4. Close the incision around the tube to prevent leakage. Hold it by hand or tie it off. Make sure the tube does not pass the bifurcation into either the right or left pulmonary artery.
5. Point the upper end of the trachea into a 10 liter bucket.
6. Turn on the tap to a pressure of about 3 kg/cm³.
7. After the lungs are inflated, allow 12 liters of fluid to flow out of the trachea.
8. Filter the sample through a 400-mesh sieve (38 μ m apertures).
9. Wash the contents of the sieve into a 1 liter bucket.
10. Pour the sieved material into petri dishes and examine it using a dissecting microscope.

Comment

Approximately 89% of the total number of worms found by Andrews and James (1994) were recovered in the first four liters of fluid collected.

Lung Parenchyma

Postmortem

Migrating larvae of several species of nematodes may reside or pass through lung tissue. Adults of some species (e.g. *Muellarius capillaris*) occur in parenchyma. Palpate the lungs for cysts. Remove approximately 25 cm² of tissue, or cysts, from the infected lung.

Diagnostic

Nematode larvae are recovered by digesting approximately 40 g of tissue, followed by concentrating nematodes using the Baermann technique.

Papain Digestion Procedure

Lung nodules can be digested in papain. Dissolve 90 mg of papain in 50 ml of distilled water. Add 2 ml of this stock solution to 48 ml of distilled water to make a digest solution containing 3.6 mg of papain per 50 ml distilled water. Filter the solution before use.

Procedure

1. Remove a 1 cm³ sized nodule from the lung.
2. Place the nodule in papain solution and leave for 1 to 2 hours at room temperature.
3. Remove the nodule and rinse it with 30 ml of distilled water.
4. Save the digest solution and the washings for egg and larval counts.
5. Submerge the nodule in distilled water and use fine point dissecting forceps to tease the nodule apart.

Body Cavity

Postmortem

Adult filarioid nematodes (e.g. *Setaria*) occur in the peritoneal cavity of ruminants and equines. The larval stages of the horse strongyle, *Strongylus edentatus*, migrate under the abdominal peritoneum, especially in the right abdominal wall. Open and examine the arteries of the small intestine, cecum and colon for the larval stages of *Strongylus vulgaris* in horses.

Tapeworm cysts occur in cattle, sheep, goats, etc.

Diagnostic

Diagnosis is based on finding the adults or larvae in the body cavity. The number of adults, larvae or cysts present should be noted and several of each preserved in 10% formalin for subsequent microscopic examination.

Liver

Postmortem

Several nematode larvae (*Ascaris*, *Strongylus equinus*, *S. edentatus*) occur in the liver. Remove a portion of the liver containing cysts or migrating larvae and examine.

Diagnostic

If migrating larvae are suspected, collect approximately 40 g of fresh tissue for pepsin digest and Baermann technique.

Urogenital System

Some nematodes live in the kidneys, urinary bladder or ureters (e.g. *Diioctophyma renale* and *Stephanurus dentatus* in swine; *Capillaria plica* in cats, dogs and other carnivores). These worms produce eggs which pass in the urine.

The coccidia, *Klossiella equi*, develop within the kidneys of horses, and oocysts are passed in the urine.

Diagnostic

Renal coccidiosis is diagnosed by finding oocysts within impression smears of the cut surface of the kidney. Flotation techniques (e.g. Sheather's) on ureteral contents concentrate oocysts. Tissues sections can be stained to reveal the intracellular organisms in renal tubules.

Urine Samples

Procedure

1. Collect a sample of urine.
2. Transfer the sample to a centrifuge tube and centrifuge at 1500 rpm for 2 to 3 minutes.
3. Pour off the supernatant.
4. Remove some of the sediment and place it on a microscope slide.
5. Apply a coverglass and examine.

Renal Coccidia in Waterfowl

(After Gajadhar *et al.*, 1983)

Procedure

1. Remove the kidney from the bird.
2. Place it in a container along with 100 ml of 2.5% (w/v) potassium dichromate.
3. Place kidneys and potassium dichromate in a blender and blend at low speed for 5 seconds.
4. Filter through a single layer of cheese cloth.
5. Wash once in water by centrifugation.
6. Suspend the sediment in Sheather's sugar solution.
7. Centrifuge at 170g for 3 minutes.



Comment

The culture methods have sensitivities of 81 to 97% (Kvasnicka *et al.*, 1996)

8. Transfer the material from the meniscus to a slide.
9. Apply a coverglass and examine.

Tritrichomonas foetus

Culture methods for detecting *Tritrichomonas* are more sensitive than wet mounts. Two culture techniques are used. One is 'in vitro' Diamond's Medium, which is prepared specifically to detect *T. foetus*. The other procedure, the recently introduced In-Pouch® TF System [Biomed Diagnostics, San Jose, California, U.S.A.] is now being used in many veterinary clinics throughout North America.

The In-Pouch® TF is a self-contained system with two V-shaped compartments for observing newly collected specimens in the upper chamber before incubating them in the lower chamber. Microscopic examination of each chamber is done through a plastic viewing stage.

Samples should be collected with a dry infusion pipette attached to a 20 ml syringe. For bulls, the specimen is collected by scraping the mucosa of the distal penis and the fornix area while applying suction with the syringe. In the cow, the same technique is used in the anterior vagina.

Place the specimen directly into the culture medium in the field. Incubate the inoculated culture at 37°C. The cultures are stored vertically to concentrate the organisms at the bottom. Examine the cultures microscopically after 24, 48, and 72 hours of incubation. The specimen should be viewed at a magnification of 100 x.

One test may be adequate to make a herd diagnosis if one or more bulls is infected. However, for any individual bull, three negative test results are necessary to assure that the bull is not infected (Kvasnicka, 1996).

Herbage Samples

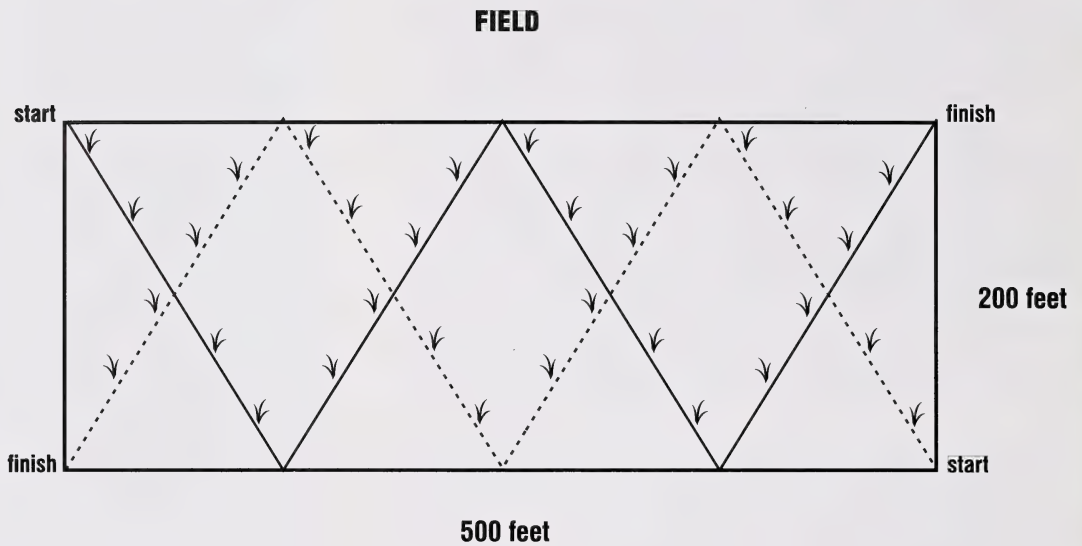
Herbage samples are used to estimate the number of infective nematode larvae on pastures. The size of the pasture and the physical properties of the forage must be assessed before sampling.

Collect random grass samples from each plot or pasture. Collect the samples in the morning before the sun dries the pasture. Begin collecting at one corner of the pasture and cross the field in a predetermined, w-shaped pattern. Stop every x paces (where x equals five times the area of the field in acres). Criss-cross the pasture following two w-shaped paths to ensure adequate coverage of the pasture (Figure 13). The total grass sample should weigh approximately 200 g. Do not collect grass closer than 15 cm to fecal pats.

Comment

- The technique recovers about 40% of the larvae present on forage (Ludwig and Johnstone, 1984).
- The amount of moisture present at the time of collection will change the larval counts. Dry conditions keep larval counts low. Rainfall or heavy dew increase the larval count.
- For horses, 50 to 100 larvae/kg of forage represents a moderate count, while >500 larvae/kg of forage is extremely high (Ludwig and Johnstone, 1984).

Figure 13
Collecting Herbage Samples



Size of field in acres. $500 \text{ feet} \times 200 \text{ feet} = 100,000 \text{ square feet} = 2.3 \text{ acres}$

Collect samples every $5 \times 2.3 \text{ acres} = 12 \text{ paces}$

Preparing Parasites for Study



Parasite Specimens

Adult worms or proglottids may be passed in the feces. They should be removed and placed in a vial containing either saline, 70% ethanol or 10% formalin.

Tapeworms

Specific identification is based on the morphology of mature and gravid segments (proglottids) and on the scolex. Occasionally, identification can be made on gravid sections passed in feces, but this is less reliable. Preserve worms in 10% formalin if specimens cannot be examined immediately. Fresh specimens can be refrigerated for up to 48 hours if they are kept moist.

Nematodes and Flukes (Trematodes)

Several worms should be preserved in 70% ethanol. Warm ethanol kills and straightens nematodes, thereby aiding specific identification. Trematodes should be flattened and preserved by applying a coverglass to the worm and perfusing fixative slowly beneath the coverglass until the worm becomes opaque. Store the fixed worms in vials containing 70% ethanol.

Protozoa – *Neospora*

Diagnosing *Neospora* depends on identifying typical lesions in the brain, heart or placenta. The preferred samples are the whole fresh fetus and a piece of placenta. At present, immunoperoxidase staining is the best way to distinguish *Neospora* from *Toxoplasma*.

Appendix I

Tabular Summary of Required Specimens and Recommended Diagnostic Procedures

	Diagnostic Stage	Specimen	Routine Test	Specialized Test
Protozoa				
Haemoprotozoa	schizont/gametocyte	fresh blood	blood film/Giemsa	--
Coccidia (general)	oocyst	fecal	Sheather's	McMaster's
	schizont/gametocyte	tissue		impression smear
Cryptosporidium sp.	oocyst	fecal	Sheather's	Giemsa
		tissue-jejunum	impression smear/Giemsa	--
Toxoplasma sp.	oocyst	fecal	--	sugar flotation s.gr. 1.15
Enteric Protozoa (general)	trophozoize	tissue	wet smear	Kohn's stain
	cyst	fecal	Sheather's	Kohn's stain
Giardia sp.	trophozoite	tissue-jejunum	wet smear	Hematoxylin
	cyst	fecal	--	ZnSO ₄
Nematodes				
Blood	microfilaria	fresh blood	blood/film/Giemsa	Knott's method
Ascarids	egg	fecal	Sheather's	--
Lungworms	egg	fecal	Sheather's	--
	larva	fecal	Baermann	--
		lung	--	digestion procedure
Oxyuris equi	egg	anal impression	scotch tape smear	--
Strongylus sp.	egg	fecal	Sheather's	--
	larva	tissue	--	necropsy
Trichinella sp.	larva	tissue (muscle)	squash	digestion procedure
Trichostrongyles	egg	fecal	Sheather's	--
	larva	fecal	--	culturing



Tabular Summary – continued

	Diagnostic Stage	Specimen	Routine Test	Specialized Test
Cestodes (Tapeworms)				
<i>Taenia sp.</i>	egg	fecal	Sheather's	--
	cysticercus	tissue	--	squash preparation
<i>Echinococcus granulosus</i>	egg	fecal	Sheather's	--
	hydatid cyst	cyst or hydatid fluid	sedimentation	squash preparation
<i>Moniezia sp.</i>	egg	fecal	Sheather's	--
Digenea (Flukes)				
<i>Dicrocoelium dendriticum</i>	egg	fecal	sedimentation	--
<i>Fasciola hepatica</i>	egg	fecal	sedimentation	--
<i>Fascioloides magna</i>	egg	fecal	sedimentation	--
Acanthocephala				
<i>Acanthocephala</i>	egg	fecal	sedimentation	--
Arthropods				
Ticks	adult	tissue/parasite	direct examination	--
Lice	adult	tissue/parasite	direct examination	Hoyer's
Fleas	adult	parasite	direct examination	Hoyer's
Mites	adult	tissue	scraping/glycerine	KOH digest
Myiasis	larva	tissue/parasite	direct examination	Hoyer's for spiracular plates

Appendix II

Solutions Commonly Used in Veterinary Diagnostic Parasitology

Acetic Acid, 3%

Glacial acetic acid	3 ml
Distilled water	97 ml

Acid Alcohol, 90%

Glacial acetic acid	4.5 ml
Ethyl alcohol 90%	995.5 ml

Acid Solution

(To kill free-living nematodes)

Concentrated HCl	1 ml
Distilled water	30 ml

Carbol-fuchsin Stain

(For Kinyoun Stain)

Basic fuchsin	4 g
Alcohol, 95% ethanol	20 ml
Phenol crystals	8 g
Distilled water	100 ml

Ferric Ammonium Sulfate, 2%

Ferric ammonium sulfate	2 g
Distilled water	98 ml

Formalin, 2%

Formaldehyde (40% HCOH) ...	2 ml
Distilled water	98 ml

Formalin, 4 % Buffered

Formaldehyde (40% HCOH)	10 ml
Distilled water	90 ml
NaH ₂ PO ₄ • H ₂ O	0.4 g
Na ₂ HPO ₄ • H ₂ O	0.6 g

Giemsa's Stain

(After Lillie, 1969)

Azure A eosinate	0.5 g
Azure B eosinate	2.5 g
Methylene Blue eosinate	2.0 g
Methylene Blue chloride	1.0 g

To prepare the stain, dissolve 0.5 g powder dye in 33 ml of glycerine; add 33 ml methyl alcohol. Let the solution stand for 24 hours before use.

Giemsa's Stain

(After Meyer and Olsen, 1975)

Stock Solution:

Giemsa's powder (commercial source)	2 g
Glycerine	66 ml
Methyl alcohol, absolute	66 ml

Working Solution:

Giemsa Stock solution	1 ml
Distilled water	20 ml
or Phosphate buffer (approx. 0.1 M, pH 6.5)	20 ml

Note: When Giemsa stain is prepared from a powder, acetic acid-free methanol must be used (Baker, 1970). Acetic acid lowers the pH of the solution when the methanol solution is diluted with water.

Hoyer's Solution

Distilled water	50 ml
Gum arabic flakes	30 g
Chloral hydrate	200 g
Glycerine	20 ml

Mix the ingredients in the order given. Let the solution stand at room temperature for one or two days to completely dissolve the gum arabic. A few grains of Lignin Pink or Chlorazol Black may be added to the preparation if simultaneous staining is required.

Iodine, 0.2% in 70% Ethanol

KI	0.2 g
Ethanol, 70%	100 ml

Kohn's Chlorazol Black

(After Gleason and Healy, 1965)

Chlorazol Black E 5 g

Basic solution:

Ethanol, 90 % 170 ml

Methanol 160 ml

Glacial Acetic acid 20 ml

Liquid Phenol 20 ml

Phosphotungstic acid, 1 % 12 ml

Distilled water 618 ml

Grind the Chlorazol Black E in a mortar for 3 minutes, add a small amount of 'basic solution' and continue grinding until a smooth paste is formed. Add more solution and grind for 5 minutes longer. Let the stain settle and decant the supernatant into a separate container. Add more basic solution to the sediment in the mortar and repeat the process until all the Chlorazol Black is in solution. Let stand for 4 to 6 weeks to ripen. Filter prior to use. Dilute stock solution 1:2 with basic solution and stain for 2 to 3 hours. Staining times will vary with dye lot, so some adjusting is required for each new lot of stain.

Lugol's Solution

(After Meyer and Olsen, 1975)

KI 1 g

Iodine 0.5 g

Distilled water 50 ml

Dissolve the KI in the distilled water. Iodine crystals are added to saturate the solution. Some undissolved iodine crystals should be present. Store in a brown bottle. The stock solution is good as long as iodine crystals are present.

Mayer's Albumen

(After Noble and Noble, 1962)

Fresh egg white 50 ml

Glycerine 50 ml

Sodium salicylate 1 g

Methylene Cellulose

(For slowing protozoa)

Methyl cellulose 10 g

Distilled water 90 ml

Methylene Blue

Methylene blue, crystals 0.1 g

Distilled water 1000 ml

Nolands Solution

(After Jahn and Jahn, 1949)

Phenol, saturated aqueous solution 80 ml

Formaldehyde (40% HCHO) 20 ml

Glycerine 4 ml

Gentian Violet 20 mg

Pepsin-HCl Digest Solution

Pepsin 10 g

HCl, concentrated 20 ml

Distilled water 1000 ml

Potassium Dichromate, 2.5%

Potassium dichromate 2.5 g

Distilled water 100 ml

Dissolve the potassium dichromate in 50 ml distilled water, then make up to 100 ml.

Schaudinn's Fixative

Mercuric Chloride, saturated aqueous solution 100 ml *

Ethanol, 95% 50 ml

Glacial acetic acid 7.5 ml

Add the glacial acetic acid just before using.

*** Note**

Approximately 6.9 g per 100 ml distilled water at 20° C.

Sheather's Sugar Solution

Sucrose 265 g
Distilled water 500 ml
Formalin 25 ml

The formula gives a specific gravity of 1.27.

Sodium Hydroxide, 1 % Solution

NaOH 1.0 g
Water 100 ml

Thiosulphate Solution

Sodium thiosulphate 30 g
Water 100 ml

Trichrome Stain

Glacial acetic acid 10 ml
Chromotope 2R 6.0 g
Light green SF 3.0 g
Phosphotungstic acid 7.0 g
Distilled water 1000 ml

Add the glacial acetic acid to chromotope 2R, light green SF and phosphotungstic acid in a clean flask. Swirl to mix, and allow the mixture to stand for 30 minutes. Add 1000 ml distilled water and mix thoroughly. The stain is stable and used undiluted.

Zinc Sulfate Solution

(For *Giardia*)

Zinc sulfate approx. 331 g
Distilled water 1000 ml

Use a hydrometer to adjust the specific gravity to 1.18.

References

- Alicata, J.E.** 1941. Studies on the control of the liver fluke of cattle in the Hawaiian Islands. *American Journal of Veterinary Research* 2: 152-164.
- Andrews, S.J. and F.M. James.** 1994. Further evaluation of a perfusion technique for the recovery of *Dictyocaulus viviparus* from bovine lungs. *Journal of Helminthology* 68: 81-82.
- Anderson, B.C.** 1985. Quick and easy diagnosis of cryptosporidiosis and Johne's disease. *Veterinary Medicine* (1985): 87-89.
- Baermann, G.** 1917. Eine einfache Methode zur Auffindung von Ankylostomum-(Nematoden)-Larven in Erdproben. (A simple method for isolation of *Ancylostomum* - (Nematoda) - larvae from soil samples. *Wetlevreden Batavia, Geneesk. Lab. Reestbundel* (1917): 41-47.
- Bailenger, J.** 1979. Mechanisms of parasitological concentration in coprology and their practical consequences. *Journal of Medical Technology* 41: 65-71.
- Baker, D.G., D.R. Strombeck and L.J. Gershwin.** 1987. Laboratory diagnosis of *Giardia duodenalis* infection in dogs. *Journal of the American Veterinary Medicine Association* 190: 53-56.
- Baker, J.R.** 1970. Principles of Biological Microtechnique: A study of Fixation and Dyeing. Methuen and Co. Ltd. England. 357 pp.
- Barr, S.C. and D.D. Bowman.** 1994. Giardiasis in dogs and cats. *Compendium on Continuing Education for the Practicing Veterinarian* 16: 603-606; 608-610; 614.
- Belem, P.A.D., M.R. Oliveira and C.R. Padovani.** 1993. Distribution of the number of *Eurytrema* sp. eggs per gram of feces in naturally infected cattle. *Veterinary Parasitology* 49: 325-330.
- Bello, T.R.** 1961. Comparison of the floatation of *Metastrongylus* and *Ascaris* eggs in three different levitation solutions. *American Journal Veterinary Research* 22: 597-600.
- Boag, B.** 1984. Effect of different concentrations of formalin on the preservation of *Trichostrongylus retortaeformis* (Zeder, 1800) (Nematoda). *Proceedings of the Helminthological Society of Washington* 51: 331.
- Brunsdon, R.V.** 1970. Within-flock variations in strongyle worm infections in sheep: the need for adequate diagnostic samples. *New Zealand Veterinary Journal* 18: 185-188.
- Brunsdon, R.V.** 1971. Trichostrongyle worm infection in cattle: further studies on problems of diagnosis and on seasonal patterns of occurrence. *New Zealand Veterinary Journal* 19: 203-212.

Bullock, W.L. 1980. The use of the Kohn chlorazol black fixative-stain in an intestinal parasite survey in rural Costa Rica. *Journal of Parasitology* 66: 811-813.

Busa, V. 1955. Príspevok k dynamike vyskytu mikrosetarii v krvi koni. *Veterinarsky Casopis, Bratislava* 4: 99-109.

Carrol, M.J., J. Cook and J.A. Turner. 1983. Comparison of polyvinyl alcohol and formalin-preserved fecal specimens in the formalin-ether sedimentation technique for parasitological examination. *Journal of Clinical Microbiology* 18: 1070-1072.

Chalifoux, L. and R.D. Hunt. 1970. Histochemical differentiation of *Dirofilaria immitis* and *Dipetalonema reconditum*. *Journal of the American Veterinary Medical Association* 158: 601-605.

Cheng, T.C. 1986. *General Parasitology*. 2nd ed., Academic Press Inc., Florida, U.S.A. 827 pp.

Church, E.M., J.R. Georgi and D.S. Robson. 1976. Analysis of the microfilarial periodicity of *Dirofilaria immitis*. *Cornell Vet.* 66: 333-346.

Coles, G.C., C. Bauer, F.H.M. Borgsteede, S. Geerts, T.R. Klei, M.A. Taylor and P.J. Waller. 1992. World association for the Advancement of Veterinary Parasitology (W.A.A.V.P) methods for the detection of anthelmintic resistance in nematodes of veterinary importance. *Veterinary Parasitology* 44: 35-44.

Cornish, J., M.A. Vanderwev, G. Findon and T.E. Miller. 1988. Reliable diagnosis of *Trichosomoides crassicauda* in the urinary bladder of the rat. *Laboratory Animals* 22: 162-165.

Cort, W.W., J. Ackert, D.L. Augustine and F. Payne. 1922. Investigations on the control of Hookworm disease. *American Journal of Hygiene* 2: 1-16.

Coyne, M.J., G. Smith and C. Johnstone. 1991. Fecundity of gastrointestinal trichostrongylid nematodes of sheep in the field. *American Journal of Veterinary Research* 52: 1182-1188.

Cox, D.D. and A.C. Todd. 1962. Survey of gastrointestinal parasitism in Wisconsin cattle. *Journal of the American Veterinary Medical Association* 141: 706-709.

Davies, R.B. and C.P. Hibler. 1979. Animal reservoirs and cross-species transmission of *Giardia*. In: W. Jakubowski and J.C. Hoff (ed.), *Proceedings of the National Symposium on Waterborne Transmission of Giardiasis*, U.S. Environmental Protection Agency, Cincinnati, Ohio, September 18-20, 1978. pp. 104-126.

- Davis, L.R., D.C. Boughton and G.W. Bowman.** 1955. Biology and pathogenicity of *Eimeria alabamensis* Christensen, 1941, and intranuclear coccidium of cattle. *American Journal of Veterinary Research* 16: 274-281.
- Dennis, W.R., W.M. Stone and L.E. Swanson.** 1954. A new laboratory and field diagnostic test for fluke ova in feces. *Journal of the American Veterinary Medical Association* 124: 47-50.
- Dickerson, J.W., M.L. Eberhard and P.J. Lammie.** 1990. A technique for microfilarial detection in preserved blood using nucleopore filters. *Journal of Parasitology* 76: 829-833.
- Dryden, M.W., J.E. Boyer and V. Smith.** 1994. Techniques for estimating on-animal populations of *Ctenocephalides felis* (Siphonaptera: Pulicidae). *Journal of Medical Entomology* 31: 631-634.
- Dubey, J.P.** 1973. Diagnosis of feline toxoplasmosis. *Feline Practice* 3: 14-17.
- Duncan, J.L., J.S. Gilleard and J.B. McKeand.** 1992. Diagnosis of parasitic bronchitis in cattle. *Veterinary Record* 166: 39.
- Dunn, A.M.** 1978. *Veterinary Helminthology*. 2nd ed. William Heinemann Medical Books Ltd. London, England.
- Egwang, T.G. and J.O.D. Slocombe.** 1981. Efficiency and sensitivity of techniques for recovering nematode eggs from bovine feces. *Canadian Journal of Comparative Medicine* 45: 243-248.
- Egwang, T.G. and J.O.D. Slocombe.** 1982. Evaluation of the Cornell-Wisconsin centrifugal flotation technique for recovering trichostrongylid eggs from bovine feces. *Canadian Journal of Comparative Medicine* 46: 133-137.
- Estevez, E.G. and J.A. Levine.** 1985. Examination of preserved stool specimens for parasites: Lack of value of the direct wet mount. *Journal of Clinical Microbiology* 22: 666-667.
- Eysker, M., J.H. Boersema and W.M.L. Hendriks.** 1990. Recovery of different stages of *Dictyocaulus viviparus* from cattle lungs by a combination of a perfusion and a Baermann technique. *Research in Veterinary Science* 49: 373-374.
- Faler, K. and K. Faler.** 1984. Improved detection of intestinal parasites. *Modern Veterinary Practice* (1984): 273-276.
- Frenkel, J.K.** 1975. Toxoplasmosis in cats and man. *Feline Practice* 5: 28-41.
- Gajadhar, A.A., R.J. Cawthorn, G.A. Wobeser and P.H.G. Stockdale.** 1983. Prevalence of renal coccidia in wild waterfowl in Saskatchewan. *Canadian Journal of Zoology* 61: 2631-2633.

- Garcia, L.S., T.C. Brewer and D.A. Bruckner.** 1979. A comparison of the formalin-ether concentration and trichrome-stained smear methods for the recovery and identification of intestinal protozoa. *American Journal of Medical Technology* 45: 932-935.
- Garcia, L.S. and R. Shimizu.** 1981. Comparison of clinical results for the use of ethyl acetate and diethyl ether in the formalin-ether sedimentation technique performed on polyvinyl alcohol-preserved specimens. *Journal of Clinical Microbiology* 13: 709-713.
- Georgi, J.R.** 1980. *Parasitology for Veterinarians*. 3rd Edition. W.B. Saunders Co. Toronto. 460 pp.
- Georgi, J.R., M.E. Georgi and D.J. Cleveland.** 1977. Patency and transmission of *Filaroides hirthi* infection. *Parasitology* 75: 251-257.
- Giemsa, G.** 1920. Färbemethoden für Malariaparasiten. *Zentralbl. Bakteriol.* 32: 307-313.
- Gleason, N.N. and G.R. Healy.** 1965. Modification and evaluation of Kohn's one-step staining technique for intestinal protozoa in feces or tissue. *American Journal of Clinical Pathology*. 43: 494-496.
- Gordon, H.M.C.L.** 1967. The diagnosis of helminthosis in sheep. *Veterinary Medicine Review* 2/3 (1967): 140-168.
- Gronvold, J.** 1984. Isolation of infective *Cooperia* larvae from soil samples. *Acta Vet. Scand.* 25: 139-142.
- Guy, P.A.** 1984. *Ollulanus tricuspis* in domestic cats - prevalence and methods of post-mortem diagnosis. *New Zealand Veterinary Journal* 32: 81-84.
- Hall, M.C.** 1912. A comparative study of methods of examining feces for evidence of parasitism. U.S. Department of Agriculture Bulletin 135: 1-42.
- Hargis, A.M., J.L. Blanchard and D.J. Prieur.** 1983. Diagnosis of *Ollulanus tricuspis* infection in living cats. *Feline Practice* 13: 16-19.
- Henriksen, S.A. and K. Aagaard.** 1976. En enkel flotations-og McMastermetocke. *Nordisk Veterinaermedicin* 28: 392-397.
- Herlich, H.** 1957. Preliminary observations on calves experimentally infected with *Trichostrongylus colubriformis*. *Proceedings of the Helminthological Society of Washington* 24: 139-140.
- Inderbitzen, F.** 1976. Experimentell erzeugte entwicklungs hemmung von *Dictyocaulus viviparus* des rindes. Ph.D. Thesis. University of Zurich.

- Ivens, V.R., D.L. Mark and N.D. Levine.** 1978. Principal Parasites of Domestic Animals in the United States. Biological and Diagnostic Information. Special Publication #52. College of Agriculture and Veterinary Medicine. University of Illinois. Urbana-Champaign, U.S.A. 270 pp.
- Jackson, E., F. Jackson and W.O. Smith.** 1984. Comparison of saline incubation and pepsin digest as methods for recovering *Ostertagia circumcincta* larvae from the abomasum of sheep. *Research in Veterinary Science* 36: 380-381.
- Jahn, T.L. and E.F. Jahn.** 1949. How to know the Protozoa. Wm. C. Brown Co. Iowa. 234 pp.
- Jordan, H.E. and E.L. Stair.** 1984. The importance of endoparasite counts at necropsy. *Modern Veterinary Practice* (1984): 763-766.
- Jorgensen, R.J.** 1975. Isolation of infective *Dictyocaulus* larvae from herbage. *Veterinary Parasitology* 1: 61-67.
- Kao, T.C. and B.L.P. Ungar.** 1984. Comparison of sequential, random, and hemacytometer methods for counting *Cryptosporidium* oocysts. *Journal of Parasitology* 80: 816-819.
- Kaplan, R.M.** 1994. Liver flukes in cattle: Control based on seasonal transmission dynamics. *Compendium Continuing Education for Practicing Veterinarians* 16:687-693.
- Kingsbury, P.A.** 1965. Relationship between egg counts and worm burdens of young sheep. *Veterinary Record* 77: 900-901.
- Kloosterman, A.** 1971. Observations on the epidemiology of trichostrongylosis of calves. *Meded Landbouwhogeschool Wageningen* 71: 1-114.
- Kohn, J.** 1960. A one-step permanent staining method for fecal protozoa. *Dapin Refu.* 19: 160.
- Kvasnicka, W.G., M. Hall, D. Hanks, E. Ehol and B. Kearley.** 1996. Current concepts in the control of bovine Trichomoniasis. *The Compendium of Continuing Education for the Practicing Veterinarian* 18(04 Supplement): S105-S108; S110-S111; S125.
- Kyvsgaard, N.C.** 1990. Distribution of *Taenia saginata* cysts in carcasses of experimentally infected calves and its significance for routine meat inspection. *Research in Veterinary Science* 49: 29-33.
- Lancaster, M.B. and B. Timms.** 1989. A comparison between formal saline and Mirsky's fluid as fixatives for nematodes. *Systematic Parasitology* 13: 135-139.


- Larkin, H.A.** 1985. Laboratory Practice Part 7. Examination of skin scrapings for ectoparasites. *Irish Veterinary Journal* 39: 51-55.
- Larkin, H.A.** 1986. Making and examining a blood smear. *Irish Veterinary Journal* 40: 78-83.
- Lautenslager, J.P.** and **J.O.D. Slocombe.** 1984. Immunodiagnosis of occult heartworm. *Canadian Veterinary Journal* 25: 407-408.
- Leipee, J.W.G.** 1949. Continuous sedimentation for the concentration of trematode eggs in faecal suspensions. *Nature* 163: 908.
- Levine, N.D.** 1980. Nematode parasites of domestic animals and of man. 2nd edition. Burgess Publ. Co. Minneapolis, Minnesota.
- Levine, N.D.** and **I.J. Aves.** 1956. The incidence of gastrointestinal nematodes in Illinois cattle. *American Veterinary Medical Association* 129: 331-332.
- Levine, N.D.** and **D.T. Clark.** 1956. Correction factors for fecal consistency in making nematode egg counts of sheep feces. *Journal of Parasitology* 42: 658-659.
- Levine, N.D., K.N. Mehra, D.T. Clark** and **I.J. Aves.** 1960. A comparison of nematode egg counting techniques for cattle and sheep feces. *American Journal of Veterinary Research* 21: 511-515.
- Levine, R.A., S.C. Wardlaw** and **C.L. Patton.** 1989. Detection of haematoparasites using quantitative buffy coat analysis tubes. *Parasitology Today* 5: 132-134.
- Lincicome, D.R.** 1942. Fluctuations in numbers of cysts of *Entamoeba histolytica* and *Entamoeba coli* in the stools of rhesus monkeys. *American Journal of Hygiene* 36: 321-337.
- Lindsay, D.S., B.P. Stuart, B.E. Wheat** and **J.V. Ernst.** 1980. Endogenous development of the swine coccidium, *Isospora suis* Biester, 1934. *Journal of Parasitology* 66: 771-779.
- Lillie, R.D.** 1969. H.J. Conn's Biological Stains. 8th edition. The Williams and Wilkins Co. Baltimore. 498 pp.
- Long, E.G., A.T. Tsin** and **B.A. Robinson.** 1985. Comparison of the FeKal Con-Trate system with the Formalin-ethyl acetate technique for detection of intestinal parasites. *Journal of Clinical Microbiology* 22: 210-211.
- Ludwig, K.G.** and **C. Johnstone.** 1984. Use of pasture sampling to determine equine strongyle larvae contamination. *Veterinary Medicine* : 1183-1185; 1188-1189.


- Ma, P. and R. Soave.** 1983. Three-step stool examination for cryptosporidiosis in 10 homosexual men with protracted watery diarrhea. *Journal of Infectious Diseases* 147: 824-828.
- Maff.** 1986. *Manual of Veterinary Parasitology Techniques*. London, England. H.M.S.O.
- Martin, P.J., N. Anderson and R.G. Jarret.** 1989. Detecting benzimidazole resistance with faecal egg count reduction tests and in vitro assays. *Australian Veterinary Journal* 66: 236-240.
- Mascaro, C., T. Arnedo and M.J. Rosales.** 1994. Respiratory cryptosporidiosis in a bovine. *Journal of Parasitology* 80: 334-336.
- McKenna, P.B.** 1976. An evaluation of the peptic digestion technique (Herlick, 1956) for the post-mortem recovery of abomasal nematodes from sheep. *New Zealand Journal of Experimental Agriculture* 4: 235-237.
- McKenna, P.B.** 1981. The diagnostic value and interpretation of faecal egg counts in sheep. *New Zealand Veterinary Journal* 29: 129-132.
- McNabb, S.J.N., D.M. Hensel, D.F. Welch, H. Heijbel, G.L. McKee and G.R. Istre.** 1985. Comparison of sedimentation and flotation techniques for identification of *Cryptosporidium* sp. oocysts in a large outbreak of human diarrhea. *Journal of Clinical Microbiology* 22: 587-589.
- McSporran, K.D.** 1994. Canine dirofilariasis - the case for the introduction of import controls on Australian dogs entering New Zealand. *Surveillance* 21: 17-21.
- Meyer, M.C. and O.W. Olsen.** 1975. *Essentials of Parasitology*. 2nd ed. Wm. C. Brown Co. Publ. Dubuque, Iowa. 303 pp.
- Michel, J.F.** 1968. Faecal egg counts in infections of gastro-intestinal nematodes in cows. *Veterinary Record* 82; 132-133.
- Miller, B.H., P. Roudebush and H.G. Ward.** 1984. Pleural effusion as a sequela to aelurostrongylosis in a cat. *Journal of the American Veterinary Medical Association*. 185 (5): 556-559.
- Mitchell, A.J.** 1989. Squash-plate technique for detecting Asian tapeworms in fish. *Journal of Aquatic Animal Science* 1: 243-244.
- Mtambo, M.M.A., A.S. Nash, D.A. Blewett and S.Wright.** 1992. Comparison of staining and concentration techniques for detection of *Cryptosporidium* oocysts in cat faecal specimens. *Veterinary Parasitology* 45: 49-57.
- Muscoplat, C.C., J.V. Sshoster, C.A. Osborne and D.W. Johnson.** 1977. Density gradient separation of lymphocytes, eosinophils, and microfilaria from blood of dogs infected with *Dirofilaria immitis*. *American Journal of Veterinary Research* 38: 2095-2096.


- Mwegoha, W.M. and R.J. Jorgensen.** 1977. Recovery of infective third stage larvae of *Haemonchus contortus* and *Ostertagia ostertagi* by migration in agar gel. *Acta Veterinaria Scandinavica* 18: 293-299.
- Newcomb, K.M., B.A. Michael, B.P. Siebert and J. Guerrero.** 1984. Polar plugged eggs in a feline fecal specimen. *Feline Practice* 14: 19-20.
- Noble, E.R. and G.A. Noble.** 1962. *Animal Parasitology: Laboratory Manual.* Lea and Febiger. Philadelphia. 120 pp.
- Nunes, C.M., I.L. Sinhorini and S. Ogassawara.** 1994. Influence of soil texture in the recovery of *Toxocara canis* eggs by a floatation method. *Veterinary Parasitology* 53: 269-274.
- Oakley, G.A.** 1980. *The recovery of Dictyocaulus viviparus* from bovine lungs by lung perfusion: a modification of Inderbitzen's method. *Research in Veterinary Science* 29: 395-396.
- O'Grady, M.R. and J.O.D. Slocombe.** 1980. An investigation of variables in a fecal floatation technique. *Canadian Journal of Comparative Medicine* 44: 148-154.
- Oliver, D.G., P. Singh and D.E. Allison.** 1988. Trichina detection techniques as applied to a high-speed slaughterhouse environment. *Agri-Practice* 9: 45-48.
- Parnell, T.W., C. Rayski, A.M. Dunn and G.M. MacKintosh.** 1954. Some observations on the worm egg counts of Scottish hill lambs. *Journal of Helminthology* 28: 205-219.
- Parsons, S., C.G. MacKintosh and D.A. Wharton.** 1994. A comparison of lungworm faecal larval counts and trichostrongyloid faecal egg counts between red deer (*Cervus elaphus*) and red deer x wapiti F1 hybrids. *New Zealand Veterinary Journal* 42: 110-113.
- Pennington, N.E. and C.A. Phelps.** 1969. Canine filariasis on Okinawa, Ryukyu Island. *Journal of Medical Entomology* 6: 59-67.
- Pitts, R.P., D.C. Twedt and K.A. Mallie.** 1983. Comparison of duodenal aspiration with fecal flotation for diagnosis of giardiasis in dogs. *Journal of the American Veterinary Medical Association* 182: 1210-1211.
- Pohjola, S.** 1984. Negative staining method with nigrosin for the detection of cryptosporidial oocysts: a comparative study. *Research in Veterinary Science* 36: 217-219.
- Price, D.L.** 1972. Hepatic, intestinal and pulmonary trematodes. In: *CRC Handbook on Clinical Laboratory Science. Section E: Clinical Microbiology.* Vol. II. von Graevenitz, A., (ed.). CRC Press. Cleveland, U.S.A.

- Pullan, N.B.** and **M.M.H. Sewell.** 1981. A modified procedure for the extraction of infective nematode larvae from bovine faeces. *Veterinary Research Communications* 4: 307-310.
- Reinemeyer, C.R.** and **R.P. Herd.** 1986. Comparison of two techniques for quantitation of encysted cyathostome larvae in the horse. *American Journal of Veterinary Research* 47: 507-509.
- Riek, R.F., H.N. Turner, M. McKeevett** and **F.H.S. Roberts.** 1958. Adjustments for faecal worm egg counts from cattle based on faecal consistency and on age and body weight of hosts. *Australian Journal of Agricultural Research* 9: 391-402.
- Richie, L.S.** 1948. An ether sedimentation technique for routine stool examinations. *Bulletin of the U.S. Medical Department* 8: 326.
- Rivera-Anaya, J.D.** and **J.M. de Jesus.** 1952. An improved technique for the microscopic diagnosis of liver fluke infection in cattle. *Journal of the American Veterinary Medical Association* 120: 203-204.
- Roberts, F.H.S., P.J. O'Sullivan** and **R.F. Riek.** 1951. The significance of faecal egg counts in the diagnosis of parasitic gastro-enteritis of cattle. *Australian Veterinary Journal* 27: 16-18.
- Robinson, A.F.** and **C.M. Heald.** 1989. Accelerated movement of nematodes from soil in Baermann funnels with temperature gradients. *Journal of Nematology* 21: 370-378.
- Ross, J.G.** and **J. Armour.** 1960. The significance of faecal egg counts and the use of serum albumen levels and packed cell volume percentages to assess pathogenicity of helminthiasis. *Veterinary Record* 72: 137-139.
- Rossanigo, C.E.** and **L. Gruner.** 1991. Accuracy of two methods for counting eggs of sheep nematode parasites. *Veterinary Parasitology* 39: 115-121.
- Rubin, R.** 1967. Some observations on the interpretations of faecal egg counts. *American Journal of Veterinary Clinical Pathology* 1: 145-148.
- Samuel, W.M.** and **J.B. Gray.** 1982. Evaluation of the Baermann Technique for recovery of lungworm (Nematoda: protostrongylidae) larvae from wild ruminants. *Northern Sheep and Goat Council* 3:232-243.
- Schneider, T.** and **S. Kohler-Bellmer.** 1993. ELISA in the identification of cattle herds at risk from dictyocaulosis. *Veterinary Record* 132: 167.
- Schulz-Key, H.** 1978. A simple technique to assess the total number of *Onchocerca volvulus* microfilariae in skin snips. *Tropenmed. Parasit.* 29: 51-54.
- Schulz-Key, H., E.J. Albiez** and **D.W. Butlner.** 1977. Isolation of living adult *Onchocerca volvulus* from nodules. *Tropenmed. Parasit.* 28: 428-430.


- Schulz-Key, H.** and **M. Karam.** 1984. Quantitative assessment of microfilariae and adults of *Onchocerca volvulus* in ethanol-fixed biopsies and nodules. Transactions of the Royal Society of Tropical Medicine and Hygiene 78: 157-159.
- Sheather, A.L.** 1923. The detection of intestinal protozoa and mange parasites by a floatation technique. Journal of Comparative Pathology and Thereontology 36: 266-275.
- Smith, E.K.** 1988. How to detect common skin mites through skin scrapings. Veterinary Medicine (1988): 165-170; 183.
- Soulsby, E.J.L.** 1982. Helminths, Arthropods and Protozoa of Domesticated Animals. 7th ed. Bailliere Tindall. London, England. 809 pp.
- Spencer, F.M.** and **L.S. Monroe.** 1961. The Color Atlas of Intestinal Parasites. Charles C. Thomas Publisher, Springfield, Illinois. 142 pp.
- Steffan, P., S.V.A.A. Henriksen** and **P. Nansen.** 1989. A comparison of two methods and two additives for faecal cultivation of bovine trichostrongyle larvae. Veterinary Parasitology 31: 269-273.
- Studer, A.D.** and **G.D. Pancari.** 1977. Comparative evaluation of qualitative ovassay fecal diagnostic system. Practicing Veterinarian 49: 14-16.
- Subcommittee on Laboratory Standards.** 1977. Procedures suggested for use in examination of clinical specimens for parasitic infection. Journal of Parasitology 63: 959-960.
- Sutherland, R.J.** and **A.R. Clarkson.** 1984. Giardiasis in intensively reared Saanen kids. New Zealand Veterinary Journal 32: 34-35.
- Swanson, L.E.** and **H.H. Hopper.** 1950. Diagnosis of liver fluke infection in cattle. Journal of the American Veterinary Medical Association 117: 127-129.
- Swartzwelder, J.C.** 1939. A comparison of five laboratory techniques for the demonstration of intestinal parasites. Journal of Tropical Medical Hygiene 42: 185-187.
- Taffs, L.F.** 1976. Pinworm infections in laboratory rodents: a review. Laboratory Animals 10: 1-13.
- Thomson, R.B. JR., R.A. Haas** and **J.H. Thompson.** 1984. Intestinal parasites: The necessity of examining multiple stool specimens. Laboratory Medicine Mayo Clinic Proceedings 59: 641-642.
- Todd, K.S., N.D. Levine** and **E.L. Anderson.** 1970. An evaluation of the Baermann technique using infective larvae of *Haemonchus contortus*. Proceedings of the Helminthological Society of Washington 37: 57-63.

- 
- Truant, A.L., S.H. Elliot, M.T. Kelly and J.H. Smith.** 1981. Comparison of formalin-ethyl ether sedimentation, formalin-ethyl acetate sedimentation and zinc sulphate flotation technique for detection of intestinal parasites. *Journal of Clinical Microbiology* 13: 882-884.
- Tubbs, R.C.** 1987. Controlling coccidiosis in neonatal pigs. *Veterinary Medicine* (1987): 646-647; 649-650.
- Uhlinger, C.A.** 1993. Uses of faecal egg count data in equine practice. *The Compendium for Continuing Education for Veterinary Practitioners* 15: 742-749.
- Wassall, D.A.** 1991. The use of an ELISA for the serodiagnosis of parasitic bronchitis in cattle. *Veterinary Record* 165: 353.
- Watson, J.M.** 1947. A modification of the zinc sulfate centrifugal floatation technique for the concentration of helminth ova and protozoa cysts in feces. *Annals of Tropical Medical Parasitology* 41: 43-45.
- Willmott, S. and E.R.N. Pester.** 1952. Variations in faecal egg-counts in paramphistome infections as determined by a new technique. *Journal of Helminthology* 26: 147-156.
- Wilson, G.I.** 1957. Comparison of the DFC and McMaster egg-counting techniques as applied to nematode parasites of sheep. *Journal of Parasitology* 43 (suppl.): 20.
- Wilson, I.D.** 1934. Sodium chloride vs cane sugar for parasite egg floatation. *Cornell Veterinarian* 24: 79-80.
- Wong, M.M. and J.W. Thomford.** 1991. Serodiagnosis of prepatent Dirofilariasis: Problems and significance. *Journal of the American Hospital Association* 27: 33-38.
- Young, K.H., S.L. Bullock, D.M. Melvin and C.L. Spruill.** 1979. Ethyl acetate as a substitute for diethyl ether in the formalin-ether sedimentation procedure. *Journal of Clinical Microbiology* 10: 852-853.
- Zimmer, J.F. and D.B. Burrington.** 1986. Comparison of four techniques of fecal examination for detecting canine giardiasis. *Journal of the American Animal Hospital Association* 22: 161-167.





Bibliothèque nationale du Canada
3 3286 51356 1387



Alberta
AGRICULTURE, FOOD AND
RURAL DEVELOPMENT
AGDEX 650-1

Printed in Canada